

Dental implant

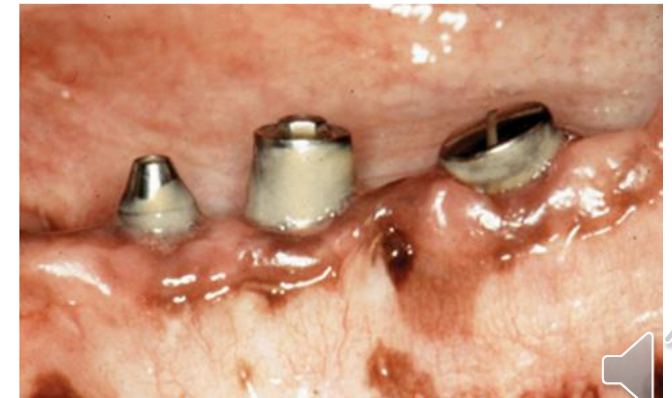Dental implant has become an established therapy in dentistry in order to replace missing teeth in different clinical situations

- The success rate of about 83% after 16 years follow-up have reported
- Under care and attention of indications, anatomical and intra-individual limiting factors, insertion of dental implants seems to represent a **safe** treatment
- However, in the last decades increasing evidence raised on the presence of peri-implant inflammations representing one of the most frequent complications affecting both the surrounding soft and hard tissues, which can lead to implant loss
- Therefore, strategies for prevention and treatment of peri-implant disease should be integrated with rehabilitation concepts in dentistry

Definition and pathogenesis

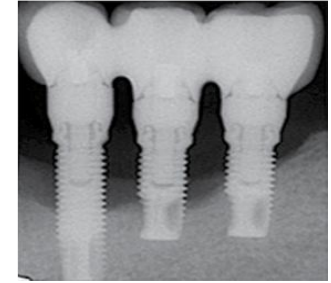
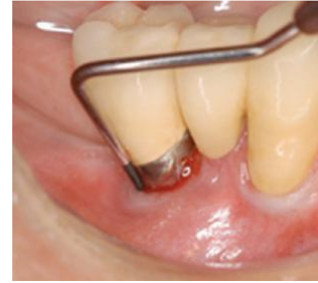In analogy to gingivitis and periodontitis, affecting the periodontium of natural teeth, mucositis and peri-implantitis are an inflammation and destruction of soft and hard tissues surrounding dental implants

- **Mucositis** can be described as bacteria-induced, reversible inflammatory process of the peri-implant soft tissue with redness, swelling and bleeding on probing



Whereas **peri-implantitis** is a progressive and irreversible disease of implant surrounding hard and soft tissues and is accompanied with bone resorption, decreased osteointegration, increased pocket formation and purulence

- Type and shape of the implant, abutment and supra-structure prosthetic material can affect the peri-implant soft and hard tissues



Etiology and epidemiology

There are several reports on the prevalence of mucositis and peri-implantitis that differ between 5 - 63.4 %

- Based on the Six European workshop in Periodontology report, the incidence of mucositis is up to 80% and the peri-implantitis is between 28 - 56 %
- This underlines the fact that the bone remodeling processes often result in marginal bone loss during the first weeks after abutment connection, which can not be regarded as peri-implantitis
- This led to the recommendation to take a radiograph after insertion of the supra-structure

A spectrum of pathogenic germs can be detected such as ***Prevotella intermedia***, ***Prevotella nigrescens***, ***Streptococcus constellatus***, ***Aggregatibacter actinomycetemcomitans***, ***Porphyromonas gingivalis***, ***Treponema denticola*** and ***Tannerella forsythia***

- However, in contrast to periodontitis, peri-implantitis lesions can harbour bacteria that are not part of the typical periodontopathic bacteria such as ***Staphylococcus aureus***, which appear to play a predominant role for the development of a peri-implantitis and showed a high affinity to titanium

Risk factors and prevention

- Implant loss may occur in up to one year after insertion and called **early implant loss**
- While **delay implant loss** is considered when the time of implant loss is more than one year

The risk factors or circumstances for implant loss are:

- 1- Smoking with additional significantly higher risk of complications in the presence of apposite combined IL-1 genotype polymorphism
 - 2- Limited oral hygiene and lack of patient compliance (missing check up)
 - 3- Systemic diseases, such as diabetes mellitus, cardiovascular disease and immunosuppression
 - 4- Iatrogenic causes (cementitis; does not remove the excess of luting cement)
 - 5- Soft tissue defects or poor-quality of soft tissue at the area of implantation (lack of keratinised gingiva)
 - 6- History of one or more failures of implants
- Studies indicate smoking as the greatest identifiable and most often cited risk factor for peri-implant disease followed by a history of periodontitis
 - The presence of periodontitis or cigarette smoking increase the risk for peri-implantitis up to 4.7 fold

- The impact of keratinised gingiva around dental implants has been controversially discussed, but most studies emphasise the importance of an adequate zone of keratinised tissue surrounding implant

Additional factors can be nominated on the basis of implant loss

- 1- Overloading of the implant
- 2- Faults in material and techniques
- 3- Poor bone quality at the implant area
- 4- Systemic diseases and drug therapies, which inhibit bone modulations

Therapy

The treatment of peri-implant infections comprises conservative (non-surgical) and surgical approaches

- Depending on the severity of the implant disease (mucositis, moderate or severe peri-implantitis)
- A non-surgical therapy alone might be sufficient or a step-wise approach with a non-surgical followed by a surgical treatment may be necessary

Treatment of mucositis

- One of the main aim of peri-implant therapy is to detoxify the contaminated implant surface
- Mechanical implant cleaning with titanium or plastic-curettes, ultrasonic or air polishing
- Moreover, photodynamic therapy as well as antiseptic medication (chlorhexidine, hydrogen peroxide, sodium bicarbonate and povidone (iodine))

Peri-implantitis

Infectious disease that causes an inflammatory process in the soft and hard tissues surrounding an osteo-integrated implant, leading to loss of supporting bone

Risk factors for peri-implantitis

- Tobacco use
- Poorly controlled systemic conditions (e.g. diabetes mellitus, osteoporosis, post-irradiated jaws)
- History of periodontitis and noncompliance to treatment
- Poor oral hygiene
- Parafunctional habits (e.g. bruxism)
- Iatrogenic factors (e.g. lack of primary stability and premature loading during the healing period)

Signs

- Progressive increase in probing depth
- Suppurations and exudation from peri-implant space
- Bleeding on probing
- Clinical appearance of inflamed tissue (bleeding, swelling, colour change, suppuration, and plaque/calculus accumulation)
- Progressive loss of supporting bone on follow-up radiographs

Symptoms

- No severe pain
- May have dull pain, tenderness on brushing or palpation
- Bad taste, potentially noticeable if there are purulent exudates
- Increasing mobility in case of failed implant
- lymphadenopathy

Investigation

- Verify if iatrogenic factors are involved such as faulty restoration, impacted foreign material (residual cement), loose components ..etc
- Assess if inadequate biomechanical forces are applied by evaluating the occlusion for the presence of:
 - 1- Parafunction
 - 2- Occlusal overload
 - 3- Mobility of the restorative component (remove crown to assess whether implant is mobile), fractured restorative component, fractured implant
- Look for active periodontitis in other sites
- Assess the potential of other bone pathologies
- Perform an exploratory surgery

Diagnosis

Based on the **clinical** and **radiographic** evaluation, a diagnosis of peri-implantitis is determined

Differential diagnosis

Peri-implant mucositis

Treatment

The long-term goals are to stop the progression of the disease and maintain the implant site

- Depending of the aetiology of the problem, a specific treatment can be selected
- Appropriate management of peri-implantitis often requires referral to a periodontist

Aetiology: bacterial infection

- Control the acute bacterial infection and reduce the inflammation in the tissues through:
 - 1- Mechanical debridement
 - 2- Localised and/or systemic antimicrobial therapy
 - 3- Improved patient compliance with oral hygiene until a healthy peri-implant site is established
- At the re-evaluation, if the patient does not have a satisfactory response to the non-surgical therapy, surgery should be considered. It is important to assess for possible cement entrapment

1- Detoxify the implant surface by using mechanical devices (e.g., high pressure air powder abrasive, laser decontamination) and/or applying chemotherapeutic agents (e.g., supersaturated citric or tetracycline applied with cotton pellets or a brush)

2- Perform flap management with either or both resective and regenerative approaches, depending on the morphology and size of the bone destruction

3- Systemic antibiotics are suggested postoperatively

Aetiology: Biomechanical forces

Perform:

- An analysis of the fit of the prosthesis
- A verification of the number and position of the implants
- An occlusal evaluation

Prostheses design changes, replacing defective restorative components and correcting occlusal overload (through improvement of implant number and position, occlusal equilibration and occlusal splint for patient with parafunction) can arrest the progression of peri-implant tissue breakdown

Aetiology acting as a co-factors

Other etiologic factors may act as co-factors in the development of peri-implantitis. Nonetheless, treatment still consists of removing the bacterial infection or correcting the biomechanical forces

Possible co-factors

- Anatomical limitations: inadequate amount of bone in recipient site at the time of the implant placement
- Surgical trauma: overheating of bone during implant placement
- Compromised host response

Additional potential risk factors

- Treatment of active potential disease and improvement of oral hygiene
- Counseling the patient on tobacco cessation

Notes

- There is no consensus regarding the best regenerative material and no long-term data regarding success of regenerative treatment
- It is important for patients to understand that regenerations are neither predictable nor reliable on an integrated and restored implant. Patients must be involved in the decision to save or replace the implant
- Many techniques for implant detoxification have been used but there is not yet a defined standard protocol

Treatment of peri-implantitis

- Most of the strategies for peri-implantitis therapy are mainly based on the treatments used for teeth with periodontitis
- The bacterial colonisation of dental and implant surfaces follow similar principles
- Surgical treatments can be done using resective or regenerative approaches

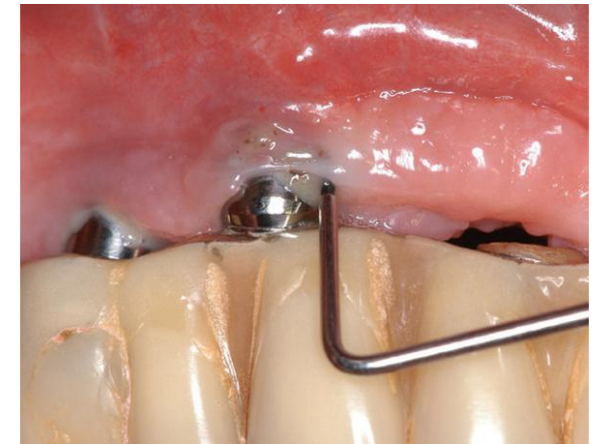
Conservative treatment

In addition to medication and manual treatment (with curettes, ultrasonic and air polishing systems), innovative techniques such as laser-supported and photodynamic therapy methods are recently described as conservative therapeutic options

Manual treatment

Basic manual treatment can be provided by Teflon, plastic and titanium curettes

- It is possible to reduce bleeding on probing scores by cleaning with piezoelectric scalers as well as with hand instruments
- No differences have been found between these methods concerning reduction of bleeding on probing, plaque index and probing depths after at least 6 months



- The air polishing systems are depending on the use of medium such as hydroxyapatite phosphate
- An abrasive air polishing medium can modify the surface of implants
- After air powder treatment cell attachment and cell viability still showed sufficient levels, but cell response decreased compared with sterile surface
- The extent of re-osteointegration of implant after air polishing therapy has been reported between 39 % and 46 % with increased clinical implant attachment and pocket depth reduction

Drug treatment

There are different modalities of treatment:

- Antiseptic rinses
- Application of systemic and locally delivered antibiotics in relation to pocket depth or different parameters such as tetracycline, doxycycline, amoxicillin, metronidazole, minocycline hydrochloride, ciprofloxacin, sulphonamides+ trimethoprim
- The effects of these antibiotics led to significantly reductions of pocket depths in a period between one to six months
- Some researchers noticed that the success rate of 58% when treating peri-implantitis with surgical debridement and the various combination of antibiotics
- The combination of metronidazole and amoxicillin on *P. gingivalis*, *Streptococcus sanguinis* and *Fusobacterium nucleatum* was found more effective than metronidazole alone

- Application of chlorhexidine resulted in the reduction of pocket depths, a higher implant adhesion and general weakening of inflammation
- **In conclusion**, local and systemic antibiotics are additional therapy but not a treatment option

Laser treatment

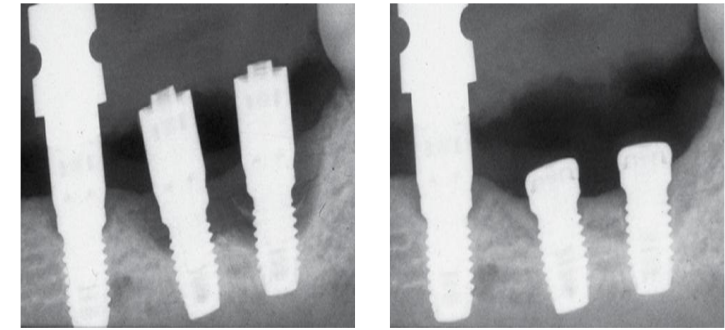
Laser is: (light amplification by stimulated emission of radiation)

- Lasers are used in the treatment of peri-implant diseases by means its bactericide mode of action such as co2 ,Diode, Er: YAG (erbium-doped: yttrium-aluminium-garnet) and Er, Cr, YSGG (erbium, chromium-doped: yttrium-scandium-gallium-garnet)
- Er.YAG and Er,Cr: YAG with a wavelength of 3 microns can reduce biofilms up to 90%
- In terms of bleeding at peri-implantitis, Er.YAG laser led to significantly better results compared to mechanical methods
- However, both methods showed no significant differences in changes of pocket depths, clinical attachment level, plaque index and gingival recession
- Although there is only few data in comparison to manual and surgical therapy, laser therapy as a treatment option has to be considered as an **adjunct**

Photodynamic treatment

It generates reactive oxygen species by multiplicity with help of a high single frequency light in combination with photosensitisers (toluidine blue)

- Photodynamic therapy generates **bactericide effects** against aerobic and anaerobic bacteria by a wave length 580 to 1400nm and toluidine blue-concentrations between 10 and 50ug/mL
- Photodynamic therapy, however; is still as an adjunctive therapy



Surgical treatment

It combines the concepts of the already mentioned non-surgical therapy with those of resective and/or regenerative procedures

Resective therapy

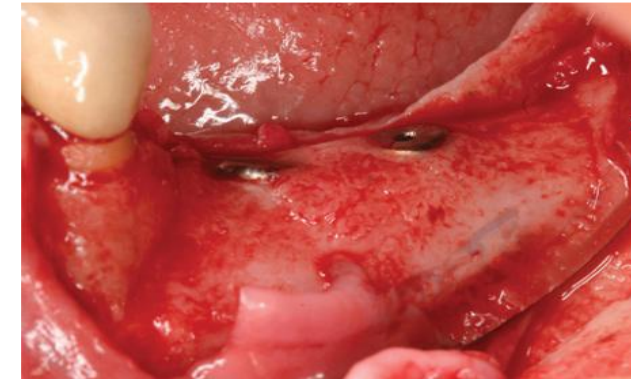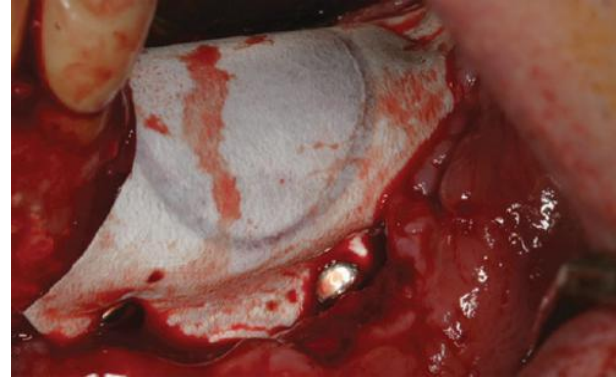
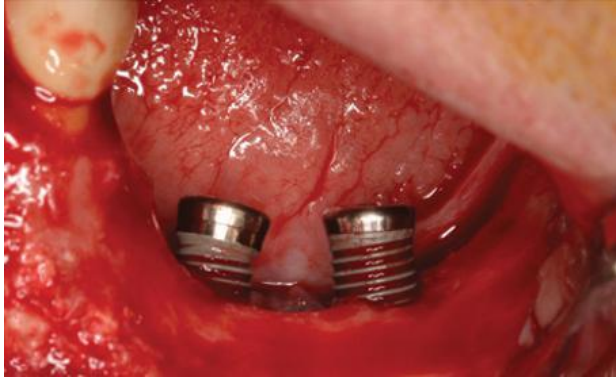Resective surgery has been shown to be effective in reduction of BOP, probing depths and clinical signs of inflammation

- The basic principles include the elimination of the peri-implant osseous defect using ostectomy and osteoplasty as well as bacterial decontamination
- Smoothing and polishing of the supra-crestal implant surface may be applied
- According to some studies shown that in patients with active peri-implant disease, surgical pocket elimination and bone re-contouring in combination with plaque control before and after surgery represent an effective treatment
- Adjuvant implant surface decontamination with antimicrobial substances led to an initially less anaerobic bacterial contamination
- Although resective therapy is recommendable treatment option, it is not suitable in highly aesthetic sensitive areas

Regenerative approaches

In case of resective surgery it may result in re-osteo-integration in only minor superficial defects

- However, full regeneration and re-osteointegration are required for aesthetic and long-time survival points of views
- In animal models, it was possible to regenerate experimentally induced defects using various graft materials and/or resorbable membranes (GTR)
- The combination of membranes and bone graft materials were superior to those using membranes or bone graft alone
- Prevention of peri-implant disease is very important than treatment



In conclusion

This AKUT protocol as schematic treatment plan by Lang

Stage	Result	Therapy
	Pocket depth (PD)< 3mm, no plaque or bleeding	No therapy
A	PD < 3mm and /or bleeding on probing	Mechanically cleaning, polishing, oral hygiene instruction
B	PD 4-5 mm, radiologically no bone loss	Mechanically cleaning, polishing, oral hygiene instructions + local anti-infective therapy (e.g. CHX)
C	PD > 5mm, radiologically bone loss < 2mm	Mechanically cleaning, polishing, microbiological test, local and systemic anti-infective therapy
D	PD > 5mm, radiologically bone loss > 2mm	Resective or regenerative surgery

Treatment of failed implants

In the presence of extensive bone loss or implant mobility, the implant may be removed and alternative options to replace the missing tooth should be discussed (replacement of failed implant, fixed partial denture, removable partial denture, etc)

References

- Clinical Periodontology and Implant Dentistry By Jan Lindhe
- Colour Atlas of Dental Medicine and Periodontology

Gingival crevicular fluid (GCF)

It is an inflammatory exudate that can be collected at the gingival margin or within the gingival crevice. It can be found in the physiologic space (gingival sulcus). As well as in the pathologic space [gingival pocket, called (transudate) or periodontal pocket, called (exudate)] between the gingiva and teeth

- GCF is derived mainly from plasma and secreted from gingival vessels which exhibit pathologically increased permeability, it releases through gingival sulcus or periodontal pocket
- GCF is continually secreted from the gingival connective tissues into the sulcus through the sulcular epithelial wall
- It is found in small amounts in clinically healthy gingival sulcus and increase in the presence of inflammation

The presence of GCF in clinically normal sulcus, despite that it is considered as an inflammatory exudate, it can be explained by the fact that it exhibits inflammation when examined microscopically

Functions

Sulcular fluid is believed to contribute to gingival defence mechanism by:

- 1- Washing the crevice carrying out the shed epithelial cells, leukocytes, bacteria and debris
 - 2- Having plasma proteins, which may influence epithelial attachment to tooth
 - 3- Containing antimicrobial agents, lysozymes, PMNLs, macrophages and immunoglobulins
- **The constituents** of GCF originate from serum, gingival tissues, bacterial and host response cells
 - The biochemical analysis of the fluid offers a non invasive means of assessing the host response in periodontal disease
 - Active phase of periodontal disease process can be measured or assessed by constituents of gingival fluid. Bacterial enzymes, bacterial degradation products, connective tissue degradation products, host mediated enzymes, inflammatory mediators, extracellular matrix proteins either together or individually can be detected in higher levels in gingival crevicular fluid during active phase of periodontitis

- These analyses mainly focus on **inflammatory markers**, such as prostaglandin E2, neutrophil elastase and beta-glucuronidase, in addition to the cellular necrotic markers (aspartate aminotransferase)
- The analysis of inflammatory markers in the GCF may assist in defining how certain systemic disease (e.g., diabetes mellitus) can modify periodontal disease and how periodontal disease can influence certain systemic disorders (atherosclerosis, preterm delivery, diabetes mellitus and some chronic respiratory diseases)
- Major factors which influence the results obtained from the analysis of GCF are not only the methods of these analysis, but the method of GCF collection as well

Methods of collection of GCF

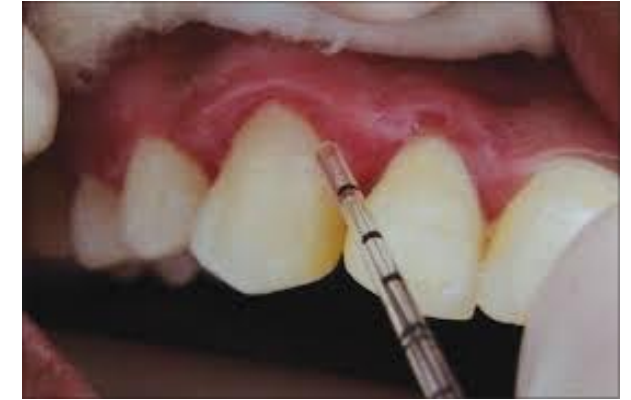Collection of GCF is a non-invasive and relatively simple procedure, so we have several methods for the collection of GCF from the gingival sulcus:

1- Gingival washing method

- In this technique the gingival crevice is perfused with an isotonic solution of fixed volume such as balanced salt solution
- The fluid collected then represents a dilution of crevicular fluid
- The simple method of this technique involves the ejection and aspiration of a known amount of solution into a given interdental gingival crevice by using needle of 50 microliter (micro syringe)

2- Capillary tubing or micropipettes

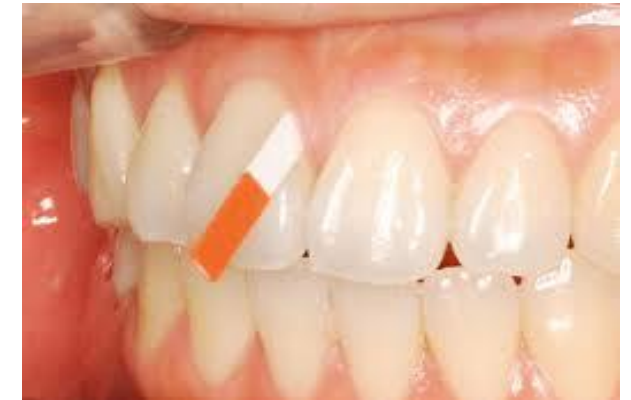- Following the isolation and drying of a site, capillary tubes of a known internal diameter are inserted into the entrance of the gingival crevice
- GCF from the crevice migrates into the tube by capillary action and because the internal diameter is known, the volume of the collected fluid can be determined by measuring the distance where the GCF has migrated



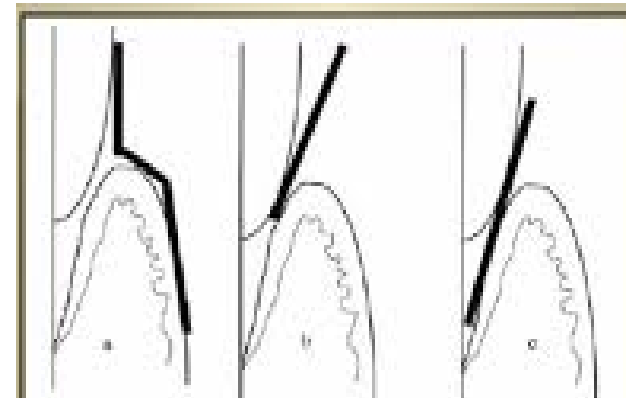
3- The use of absorbing paper strip

There are two methods by which the paper strip can be used:

a. Intra-crevicular method: the paper strip is inserted gently within the gingival crevice or until minimal resistance is felt



b. Extra-crevicular method: the paper strip is adapted on the gingiva and the hard tissue of the tooth in this region so the paper strip will absorb the seepage of GCF



- The amount of GCF collected on a paper strip can be evaluated by a variety of methods:

a. Staining: the wetted area of the strip can be made more visible by staining the strip with alcoholic solution of ninhydrin at concentration varying between 0.2 and 2%. Ninhydrin is specific for amino acids and gives a blue or purple colour. The stained region can be measured with an ordinary transparent ruler or Vernier.

b. Weighing the strip: pre-weighted strip is inserted into the gingival crevice and then determined the amount of fluid collected by weighing the sample

c. Using of periotron: it is an electronic machine which functioning units are a pair of upper and lower counterparts which can be opened and closed in order to insert or remove the strip of filter paper

- The wetness of the paper strip affects the flow of an electronic current and gives a digital readout



Composition of GCF

More than 40 compounds found in the GCF have been analysed but their origin is not known with certainty

- These compounds can be host derived or produced by the bacteria in the gingival crevice
- Many efforts have attempted to use GCF components to detect or diagnose active disease or to predict patients at risk for periodontal disease

GCF is composed from the following compounds:

1- Cellular elements

- a. Bacteria
- b. Desquamated epithelial cells
- c. Leukocytes (PMNLs, Lymphocytes and macrophages)

2- Electrolytes

- a. Potassium
- b. Sodium
- c. Calcium

3- Organic compound:

- a. Carbohydrates
- b. Protein
- c. Lipid

4- Metabolic and bacterial products

a. Lactic acid b. Urea c. Endotoxins d. Hydroxyproline

5- Enzyme and other compounds reported in GCF

a. Acid phosphatase b. Alkaline phosphatase c. Prostaglandin E2 d. Collagenase e. Lysozyme f. Cytokines as IL-1B, IL-6 and IL-8 g. Immunoglobulins as IgG, IgM, IgA

Clinical significance

The amount of GCF is greater when inflammation is present and it may be proportional to the severity of the inflammation

- GCF increases in the following situations:

1. **Circadian periodicity:** there is a gradual increase in GCF amount from 6 am to 10 pm and then decrease afterward
2. **Sex hormones:** female sex hormones increase GCF flow, probably because they enhance vascular permeability.
 - Pregnancy, ovulation and hormonal contraceptive, all increase gingival fluid production

3. **Mechanical stimulation:** chewing and vigorous gingival brushing stimulate the flow of GCF
4. **Smoking:** produces an immediate transient but marked increase in GCF
5. **Periodontal therapy:** there is an increase in GCF production during the healing period after periodontal surgery

GCF composition in relation to **systemic diseases:**

- Increase in glucose in diabetic patient
- Increase in urea, alteration of protein in kidney disease
- Increase in lactic acid in liver disease
- Increase in calcium in hyperparathyroidism
- Increase in alkaline phosphatase in bone disease (Rickets, Paget's disease)

Medications in GCF

Medications that are excreted through the GCF may be used advantageously in periodontal therapy

- **Tetracycline** is one of these medications and is effective in treating periodontitis (refractory cases) because of their concentration in the gingival crevice is 2-10 times compared to serum
- This can allow a high drug concentration to be delivered into periodontal pockets and inhibit the growth of *Aggregatibacter actinomycetemcomitans*
- **Metronidazole** is another antibiotic that has been detected in human GCF
- **Ampicillin, cephalexin, rifampicin** were detected too

References

- Clinical Periodontology and Implant Dentistry By Jan Lindhe
- Colour Atlas of Dental Medicine and Periodontology

Dentine hypersensitivity (DH)

It is the tendency of teeth to react painfully to stimuli. Acute sharp pain of short duration arises from exposed dentine and is a common finding in the adult population and have been reported to affect as many as 1 in 7 patients attending to dental clinic

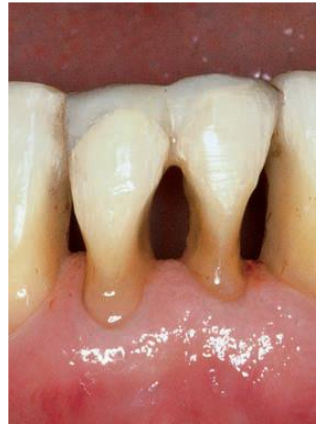- Clinical studies and questionnaire on DH indicate a prevalence of 4-74%
- It is mostly affects individuals at the end of their third decade of life, causing great discomfort
- It is experienced by women at a younger age than men
- It is mostly found in permanent canines and premolars in both dental arches
- The cervical region of the vestibular face of teeth is the most affected region
- The stimulus that triggers the onset of pain can be thermal, chemical or mechanical origin
- The most common complaint is caused by cold stimuli
- Pain may also occur by chemical stimuli such as acidic food, sweets and rarely by salty foods
- Mechanical stimulus frequently occurs when the patient rubs the sensitive area with a finger nail or tooth brush bristles during brushing, setting of pain
- The atmospheric air during mouth breathing, particularly in winter, which is associated with cold or the air of a triple syringe by dehydration also causes pain

The causes of exposure of dentine can be summarise as following:

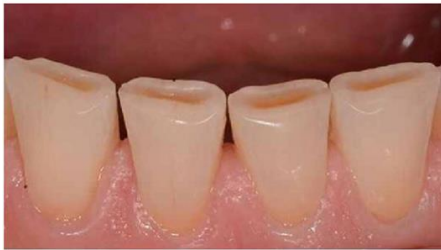- 1- Either removal of enamel covering the crown of the tooth
- 2- Or denudation of the root surface by loss of cementum and overlaying periodontal tissues

Enamel loss may result from:

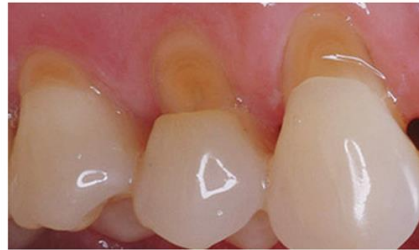- a. **Attrition** relating to occlusal abnormalities. Attrition is defined as the wearing of the teeth surfaces due to normal or abnormal function
- b. **Tooth brush abrasion** which is wearing of the teeth substance through an abnormal mechanical process as incorrect brushing which leave a deep V- shaped cervical lesion
- c. **Dietary reason** which is a mechanical process (as acids) manifested as a localized progressive destruction of enamel and dentine
 - The defects vary in shape from exposure to non bacterial acids in the diet, chemical products, medication, drugs or endogenous acids from reflux or regurgitation of stomach acid; that is substances with low pH lead to the loss of dental structure by chemical dissolution without bacterial involvement



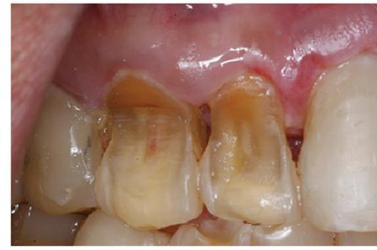Difference between dental attrition, abfraction, erosion and abrasion



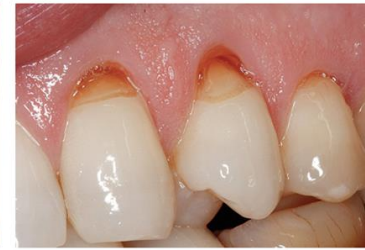Attrition



Abfraction



Erosion



Abrasion

- This process produces a more softened enamel zone.
- In the cervical area, the thinner enamel can be gradually dissolved and dentin becomes exposed to the oral environment
- The acid environment can also open the dentinal tubules even further, leading to a greater sensitivity

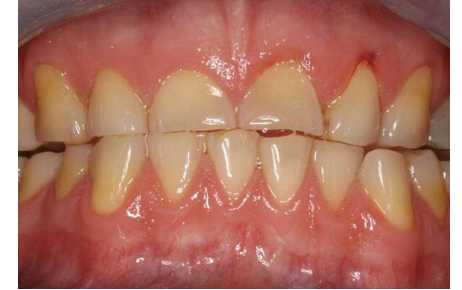d. Habits as grasping things between teeth

Cementum loss could be due to

a. Gingival recession which increase in severity with advancing age

Gingival recession may be due to

- **Mechanical trauma:** hard brush, vigorous technique
- **Predisposing anatomic factors** such as: thin gingiva, prominent roots, dehiscences, fenestrations, frenum pulls
- **Roots moved outside alveolar housing** by orthodontic appliances
- Crown or restoration margins
- Periodontal disease
- Occlusal trauma
- Trauma from teeth in opposing jaw
- Oral habits
- Poorly designed partial denture
- Tooth position
- Healing response following periodontal surgery



b. Chronic periodontal disease as the root surface may become exposed as part of the disease process and the overlaying cementum layer is thin and can easily to be removed

c. Following periodontal therapy as scaling and root planning and periodontal surgery

- Scaling and root planning may lead to removal of a thin cementum layer during periodontal scraping and expose the dentinal tubules which induce the hypersensitivity which is most likely transient and may disappear within few weeks (it reaches the peak in the first week after treatment)

d. Physiological causes: the increase in the number of teeth with root exposure is evident, as age advances

- Tooth extrusion in case of absence of an antagonist tooth, results in root exposure, which may lead to DH
- **The main symptoms of DH** are sharp pain of rapid onset and short duration provoked by different stimuli and usually resolves immediately after withdrawal of the stimulus
- Dental caries with pulpal changes have the same symptoms but in the absence of other dental pathology, these symptoms refers to **DH**

Theories of sensitivity

Many theories have been used to explain the mechanisms of DH. An early hypothesis was **1. dentinal receptor mechanism theory**, which suggests that DH is caused by the direct stimulation of sensory nerve endings in dentine

- On the basis of microscopic and experimental data, it seems unlikely that neural cells exist in the sensory part of the outer dentine. So this theory is not well accepted

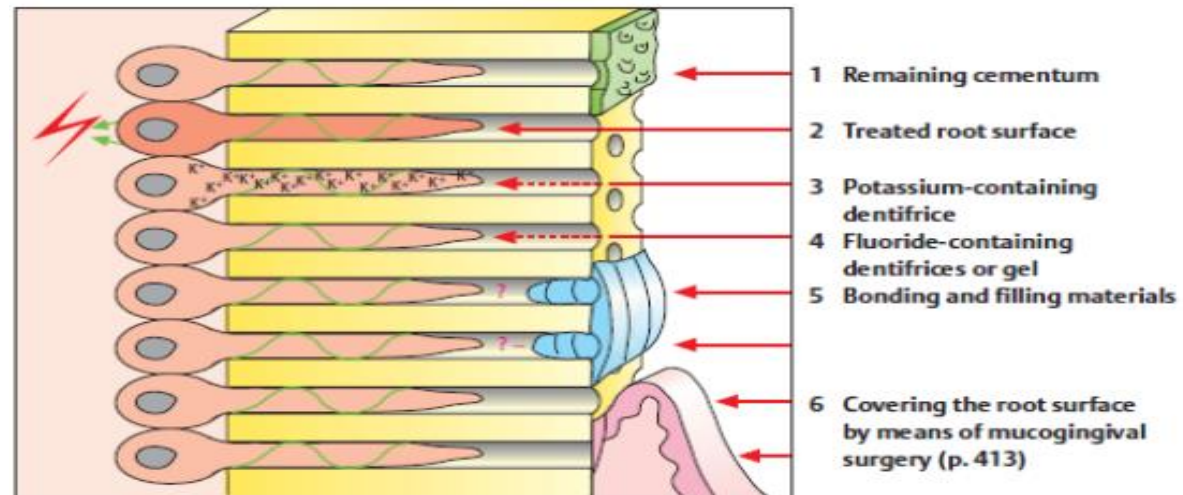

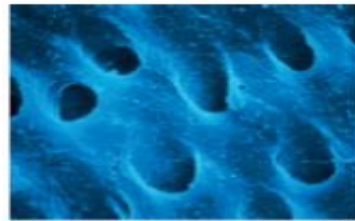
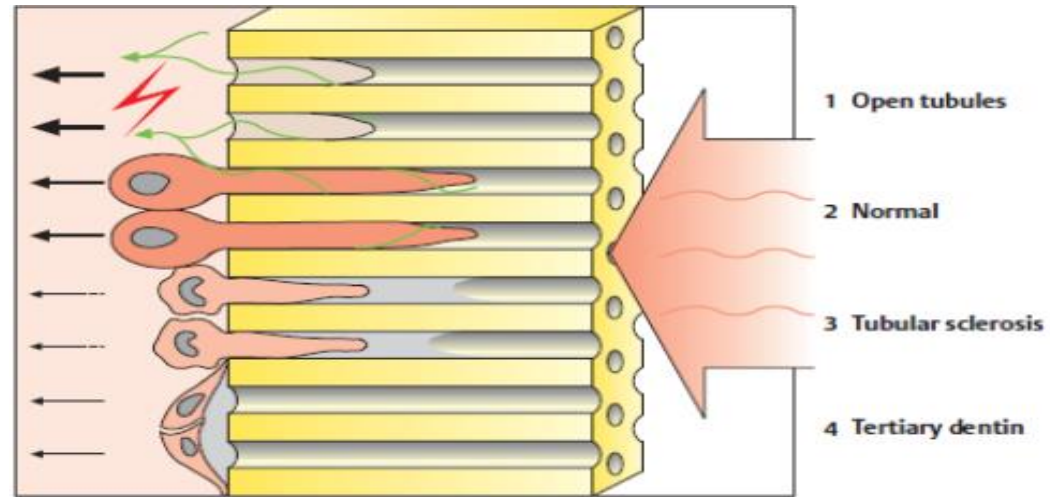
2. The odontoblast transducer mechanism proposed that odontoblasts act as receptor cells, mediating changes in the membrane potential of the odontoblasts via synaptic junctions with nerves

- This could result in the sensation of pain from the nerve endings located in the pulpodentinal border; however, evidence for the odontoblast transducer mechanism theory is generally lacking and inconclusive

Pain, caused by the fluid movement in the dentinal tubules, can be explained by the widely accepted

3. Hydrodynamic theory

- According to this theory, the transmission of stimuli to the pulp occur with a rapid movement of fluid within the dentinal tubules (normally there will be slow outward fluid flow).
- So there will be sudden shift of the dentinal tubular content which will stimulate pain receptors when a stimulus applied on exposed dentinal tubules



Diagnosis and clinical management of DH

Clinical management of DH is based on a proper diagnosis, considering its severity, localised or generalised condition, elimination of other possible causes of pain, elimination or prevention the causes

- This may involve patient counselling about oral hygiene practice (type and hardness of toothbrush, brushing before or after meals), diet (frequency of food and acidic beverage intake) and other harmful habits
- A correct history from the patient associated with a careful clinical and radiographic examination allows DH to be differentiated from other pathologies that affect the teeth

Differential diagnosis

Odontogenic origin

Cracked tooth syndrome, Fractured restoration, chipped teeth, dental caries, periodontal disease, post-restorative sensitivity, marginal leakage, pulpitis, palato-gingival groove and bleaching sensitivity

Non- odontogenic origin

Mucoskeletal, neuropathic, inflammatory (sinusitis), neurovascular, systemic (cardiac, herpes zoster, sickle cell anaemia, neoplasm), psychogenic, referred pain

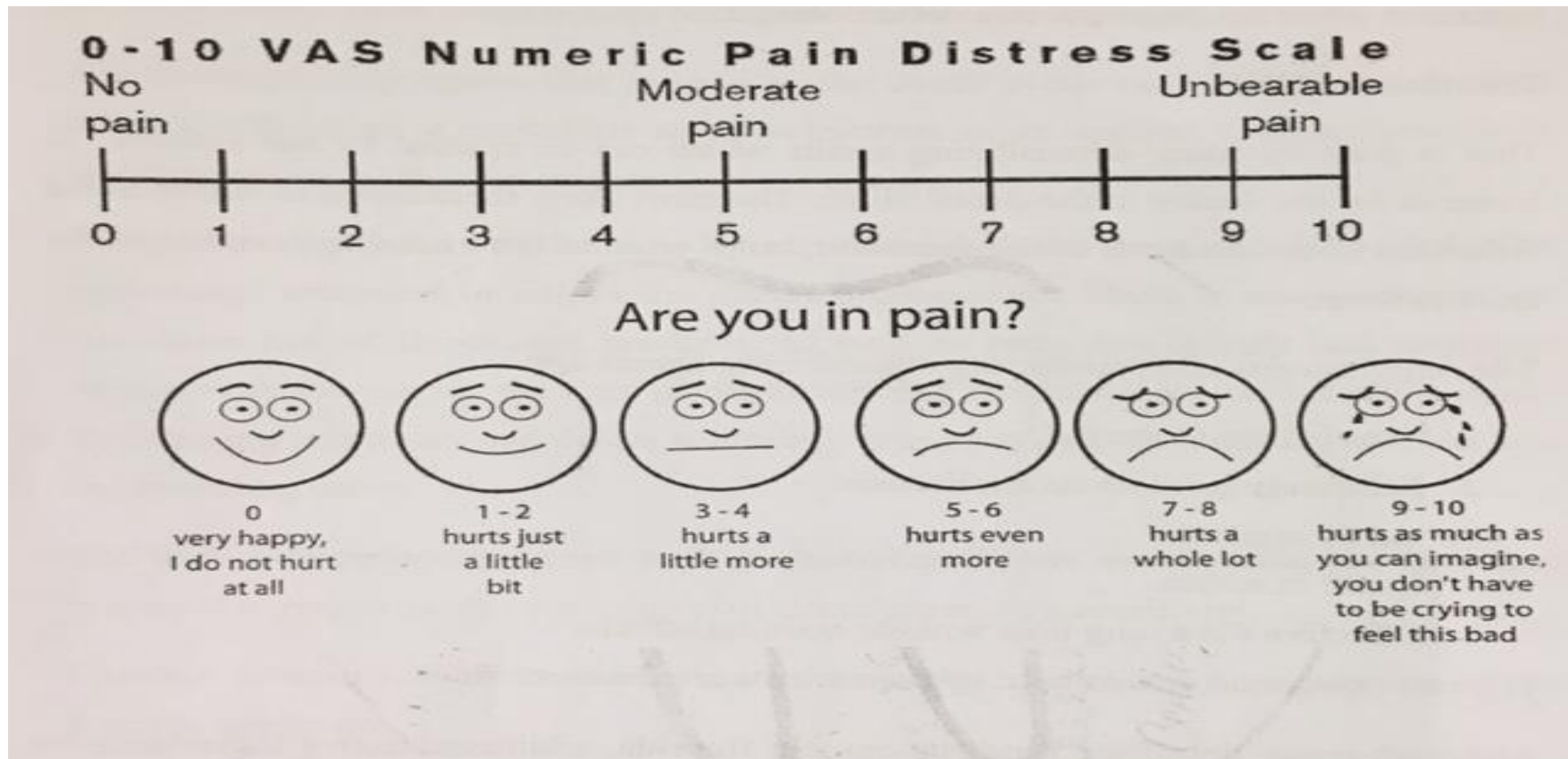
- Taking these factors into consideration, it is necessary to exclude other forms of pain or dental sensitivity
- To obtain a conclusive diagnosis of DH, first carefully evaluate, investigate and compare among the other teeth, in order to eliminate other possible causes of pain which could lead to confusion
- A good clinical history is essential and questions asked by the professional may help to collect important information that will assist in the treatment

Traditionally, dentist used to use an exploratory probe or jets of air from a triple syringe on the exposed surface or provoke a response from the patient

- Tactile stimulus with the use of a probe is the easiest, fastest and most precise method identify the areas suspected of having DH

The method consists of touching the cervically exposed dentine with a probe starting from the distal and passing towards the mesial region, examining all the teeth in the area in which the patient reports pain

- The degree of severity of pain can be quantified by means of a descriptive scale:
Slight, moderate or intensive pain or a visual analogue scale- VAS from 0-10



- Spontaneous cure occur by the natural remineralisation process in the mouth, which promotes natural tubular occlusion of dentine and pain may return because of the smear layer removal by food and acidic drinks thus explaining the cyclic characteristic of DH
- After observing the severity and number of teeth involved, an active approach to DH can begin in the cases of generalised DH, by a home method followed by in-office treatment when the first option is not successful

Treatment of DH

This can be done by using desensitising agents which can be applied by the patients at home or by dentist in the dental clinic

- The most likely mechanism of action is the reduction in the diameter of the dentinal tubules so displacement of the fluid in them

Requirements of a satisfactory desensitising agents are

1. Non-irritant to the pulp
2. Relatively painless on application
3. Easily applied
4. Rapid in action
5. Effective for long time without staining effects

The most common agents used by the patients are dentifrices

- Although many dentifrices products contain fluoride, additional active ingredients for desensitization are added as strontium chloride, potassium nitrate and sodium citrate
- An example of the dentifrices is Sensodyne which contain strontium chloride
- Other example is Emaform in which the active ingredient is formaldehyde in addition to Lacalut extrasensitive
- Also the fluoride rinsing solutions and gels can also be used after usual plaque control procedures



Mode of action

- Desensitising agents act by the precipitation of crystalline salts on the dentine surface which block dentinal tubules
- Patients must be aware that their use will not prove to be effective unless using it continuously for a period of at least 2 weeks
- The desensitising agents that is used in the dental clinic act by blocking dentinal tubules with either a crystalline salt precipitation or an applied coating (varnish or bonding agent) on the root surface
- Topical application of fluoride by a professional has been recommended after periodontal treatment in case of severe pain to relieve the patient's discomfort
- There is also evidence that the home use of fluoride products, as well as potassium nitrate, strontium acetate with fluoride, in the form of **dentifrices** and **mouthwashes** can benefit patients by reducing sensitivity and dentine solubility, acting not only in reducing DH, but also in preventing caries
- The use of desensitising agents such as potassium nitrate and fluoride has also been proposed to reduce tooth sensitivity post-dental bleaching
- Fluoride solutions and pastes have been the agents of choice, examples of the fluoride agents are:
 - 1- Sodium fluoride paste ---33% of this paste is found effective in relieving hypersensitivity
 - 2- Stannous fluoride (unstable solution, it has to be prepared freshly

It has been found that the aqueous solution of stannous fluoride in low concentration will be effective in controlling DH

- It is applied for 2 minutes, and about **an hour after application**, the patient should not eat or drink

Other desensitising agents are

- Sodium mono-fluorophosphate
- Calcium hydroxide
- Potassium oxalates
- Resin and adhesives. Etc

Recently, attempts have been made to improve the success of these treatments by using lasers. **Laser therapy** has been recommended to treat DH with effectiveness between 5.2% and 100%, depending on the type of laser and parameters used

- According to authors, lasers are more effective than other treatment, although the effectiveness diminishes in severe DH
- In severe cases where any other type of treatment is not useful so root canal treatment could be the last choice

Root dentine hypersensitivity

Patients subjected to scaling and root planning in periodontal therapy may experience increased sensitivity after instrumentation procedure of treated teeth to evaporate, tactile, thermal and osmotic stimuli

- Usually, the symptoms develop and occur during the first week after treatment and to subside or disappear within the subsequent weeks
- However, occasionally the condition may become a chronic pain problem and may persist for months or years
- In a comprehensive questionnaire survey, severe painful symptoms were reported to prevail in 26% of the subjects 6 months to 5 years after the completion of treatment, while 16% of non surgical treated cases had pain symptoms
- In a clinical trial comprising 35 patients, observer that the majority of patients subjected to non-surgical periodontal instrumentation developed sensitive teeth, while only a few teeth in a small number of patients developed highly sensitive root surfaces

The main initial symptom is the **sharp pain of rapid onset** that **disappears once the stimulus is removed**

- In more severe, long-standing cases shorter or longer periods of lingering, dull or aching pain symptoms may be provoked
- Even a minimal contact of a toothbrush with the root dentin surface may result in intense pain, a condition which may not only uncomfortable but could likely to hinder proper oral hygiene measures

- The fact that the root surfaces become sensitive to a variety of external derived stimuli after periodontal instrumentation is not surprising as **dentinal tubules become uncovered** to the oral environment and subject to hydrodynamic forces
- Hence, a variety of pain evoking stimuli including evaporating, tactile, thermal and osmotic stimuli may elicit sudden fluid shifts in the exposed tubules ,thereby inducing a painful sensation according to the hydrodynamic theory of dentine hypersensitivity
- This mechanism alone can certainly explain the sensitivity that patients experience immediately after the instrumentation procedure and during a short period afterwards
- Whereas, it does not explain why the symptoms increase over time and why the pain condition may prevail in certain patients and certain teeth

The increase in pain intensity may have one or both of the following two explanations:

1- Firstly, the smear layer formed on the root surface by scaling procedure will be dissolved within a few days. This in turn will increase the hydraulic conduction of the involved dentinal tubule and thus decrease the peripheral resistance to fluid flow across dentine. Thereby pain sensations are more readily evoked

2- Secondly, open dentinal tubules serve as pathways for diffusive transport of bacterial elements in the oral cavity to the pulp, which is likely to cause a localised inflammatory pulpal response

Note: an important factor for reducing or eliminating hypersensitivity is adequate plaque control.

However, hypersensitivity may prevent plaque control, therefore, treatment of hypersensitivity in addition to plaque control measures are very important

- Plaque control is a pivotal integral part of the prevention and treatment of root DH.
- It has been clinically observed with time that teeth in patients with excellent oral hygiene habits develop hard, smooth and insensitive root surfaces
- However, when severe symptoms of root hypersensitivity has emerged, it is difficult to motivate the patient to maintain the degree of plaque control that is necessary to allow for a natural occlusion of the dentinal tubules
- In such situations, an agent may be beneficial which has a reasonable capacity to block the open tubule, at least temporarily, so that proper oral hygiene measure can be reinforced
- In severe cases, where no remedy is achieved with any advice or treatment approach, pulpectomy and root canal treatment may be the choice

References

- Clinical Periodontology and Implant Dentistry By Jan Lindhe
- Colour Atlas of Dental Medicine and Periodontology

Occlusion

It simply means the contact between teeth. More technically, it is the relationship between the maxillary and mandibular teeth when they approach each other, as occurs during chewing or at rest

Malocclusion is the misalignment of teeth and jaws or more simply, a 'bad bite'

- Malocclusion can cause a number of health and dental problems

Static occlusion refers to contact between teeth when the jaw is closed and stationary, while **dynamic occlusion** refers to occlusal contacts made when the jaw is moving. Dynamic occlusion is also termed as articulation

Centric occlusion is the occlusion of opposing teeth when the mandible is in centric relation. Centric occlusion is the first tooth contact and may or may not coincide with **maximum intercuspation**. It is also referred to as a person's habitual bite, bite of convenience, or intercuspation position

Centric relation is a relationship between the maxilla and mandible (not to be confused with centric occlusion)

Assessing the occlusion

Extra-oral assessment

- Checking the **facial asymmetry** and **skeletal discrepancies**
- **Measuring the lower face height**

Loss of teeth and occlusal stops can result in over-closure causing a reduced face height. Over-closure is unlikely for patients with tooth wear due to dento-alveolar compensation. Over-eruption may occur in patients due to dento-alveolar development in absence of tooth wear which may result in increased face height

- **Temporomandibular joints**

The maximum extent that the patient can open is measured between the incisal edges of the upper and lower incisors. Deviation of mandible on opening or closing should be described. Clicking, crepitus and tenderness of the jaw should be noted as well

Intra-oral assessment

- Inter-cuspal position/ centric position
- Retruded contact position/ terminal hinge axis position
- Excursive movements of the mandible which include protrusion and lateral excursion

Occlusal problems

- Malocclusion is the result of, when the body trying to optimize its function in a dysfunctional environment.
- For example the maxilla can be placed too far anteriorly compared to the mandible
- This would be called a class II malocclusion
- On the contrary in case of class III when the mandible is placed too far anteriorly
- Malocclusion can also be associated with a number of problems:
 - 1- Misaligned teeth
 - 2- Periodontal problems
 - 3- The temporomandibular joints (TMJ and jaw muscles)

Trauma from occlusion

Is a term used to describe pathological alterations or adaptive changes which develop in the periodontium as a result of undue force produced by the masticatory muscles.

- Trauma from occlusion is only one of many terms that have been used to describe such alterations in the periodontium
- Other terms often used are : traumatising occlusion, occlusal trauma, traumatogenic occlusion, periodontal traumatism, overload, etc
- In addition to producing damage in the periodontal tissues, excessive occlusal force may also cause injury in, for example the temporomandibular joint, the masticatory muscles causing painful spasm , the pulp tissue or may cause excessive tooth wear

Acute and chronic trauma

Acute trauma: results from an abrupt occlusal impact as biting on hard objects, restoration or prosthetic appliances that interfere with or alter the direction of occlusal forces

- It results in tooth mobility, sensitive to percussion and increased tooth mobility
- If the force is dissipated by a shift in the position of the tooth or by wearing or correction of the restoration, the injury heals and the symptoms subside
- Otherwise, periodontal injury may worsen and develop into necrosis, accompanied by periodontal abscess formation or may persist as a symptom-free, chronic condition
- Acute trauma can also produce cementum tears

Chronic trauma: is more common than acute form and is greater clinical significance

- It most often develops from gradual changes in occlusion produced by tooth wear, drifting, movement and or extrusion of teeth combined with parafunctional habits such as bruxism and clenching rather than as a sequence of acute periodontal trauma

Types of occlusal forces

Physiological normal occlusal forces in chewing and swallowing: small and rarely exceeding 5N (Newton)

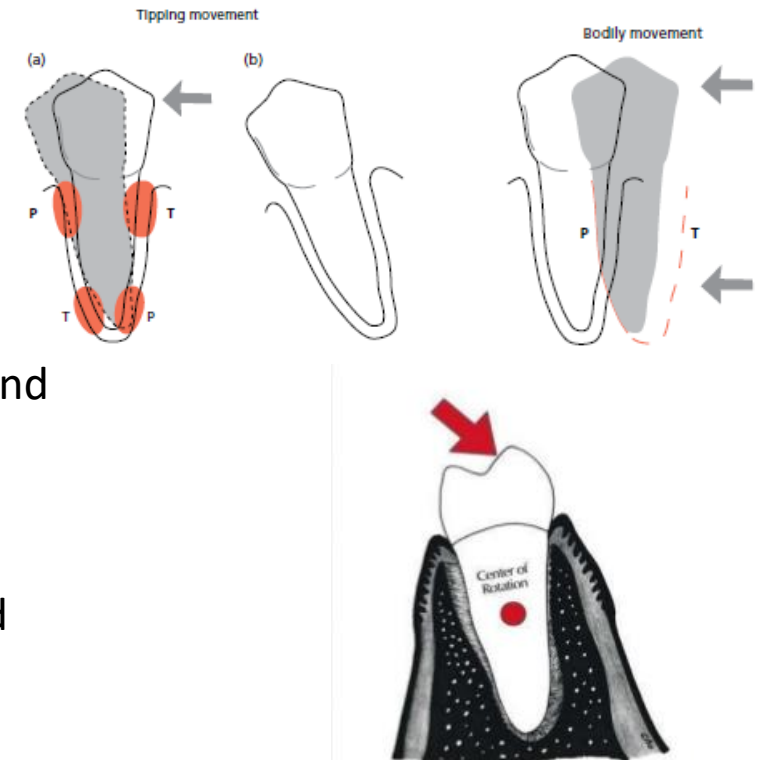
- They provide the positive stimulus to maintaining the periodontium and the alveolar bone in a healthy and functional condition

Impact forces: mainly high but of short duration. The periodontium can sustain high forces during a short period, however, forces exceeding the viscoelastic buffer capacities of the periodontal ligament will result in fracture of tooth and bone

Continuous forces: very low forces (for example, orthodontic forces), but continuously applied in one direction are effective in displacing a tooth by remodeling the alveolus

Jiggling forces: intermittent forces in two different directions (premature contacts on, for example, crowns, fillings) result in widening of the alveolus and in increased mobility

- Under the force of occlusion, a tooth rotates around a fulcrum or axis of rotation, which is in a single rooted teeth in the junction between the middle third and the apical third of the clinical root, this creates areas of pressure and tension on opposite sides of the fulcrum



When jiggling forces, occur which is coming from different and opposite directions, causing more complex histological changes in the ligament

- Theoretically the same events (hyalinisation, resorption) occur, however, they are not clearly separated.
- There are no distinct zones of pressure and tension

Types of trauma from occlusion

The tissue injury associated with trauma from occlusion is often divided into primary and secondary

1- Primary occlusal trauma: the primary form includes a tissue reaction (damage) which is elicited around a tooth with normal height of the periodontium

- Examples include periodontal injury produced around teeth with a previously healthy periodontium as:
- Insertion of high fillings
- Insertion of prosthetic replacement that create excessive force on abutments and antagonistic teeth
- Drifting movement or extrusion of teeth into spaces created by un replaced missing teeth
- Orthodontic movement of teeth into functionally unacceptable position

2- Secondary occlusal trauma: is related to situations in which occlusal forces cause injury in the periodontium of reduced height

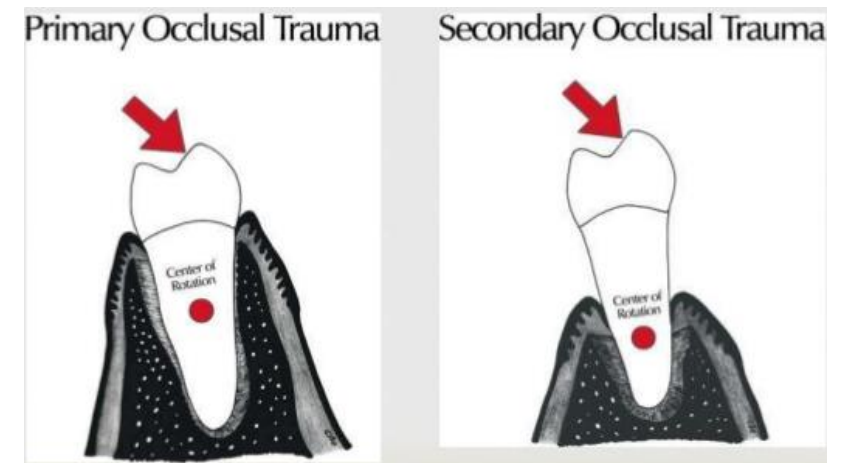
- A third type mentioned in the literature termed and related to secondary trauma from occlusion

Combined occlusal trauma: injury from an excessive occlusal forces on a diseased periodontium in this case, there is a gingival inflammation, some pocket formation and the excessive occlusal forces are generally from parafunctional movements

- This reduces the periodontal attachment areas and alters the leverage on the remaining tissues
- The periodontium become more vulnerable to injury and previously well-tolerated occlusal force become traumatic

The distinction between a primary and secondary form of injury, primary and secondary occlusal trauma-serves no meaningful purpose, since the alterations which occur in the periodontium as a consequence of trauma from occlusion are similar and independent of the height of the target tissue, i.e. the periodontium

- It is however, important to understand that symptoms of trauma from occlusion may develop only in situations when the magnitude of the load elicited by occlusion is so high that the periodontium around the exposed tooth cannot properly withstand and distribute the resulting force with unaltered position and stability of the tooth involved
- This means that in cases of severely reduced height of the periodontium even comparatively small forces may produce traumatic lesions or adaptive changes in the periodontium



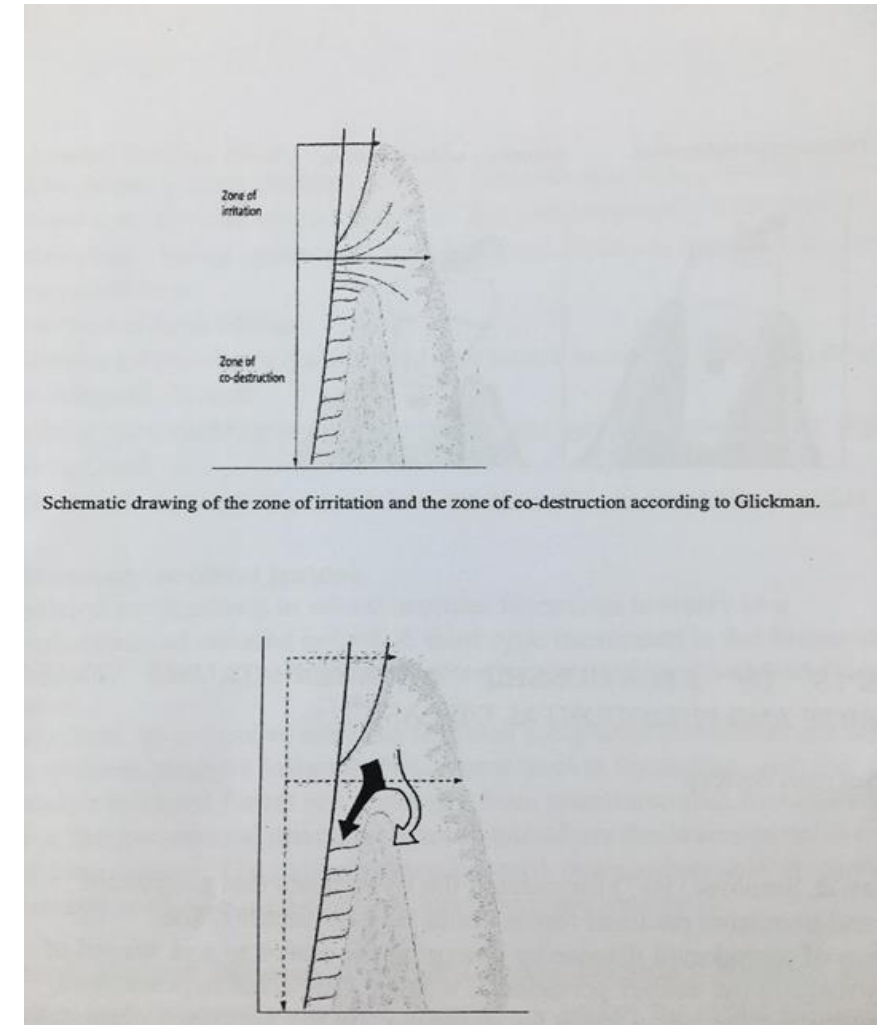
Concepts of relationship between trauma from occlusion and periodontal disease

1- Glickman concept

Glickman and Smulow 1967 formulated a hypothesis that premature contacts and excessive occlusal forces could be a co-factor in the progression of periodontal disease by changing the pathway and spread of inflammation into the deeper periodontal tissues

- Glickman hypothesised that the gingival zone was a **zone for irritation** by the microbial plaque, the supra-crestal fibres were then considered to be a **zone of co-destruction** under the influence of a faulty occlusion

The inflammatory lesion in the zone of irritation can (in teeth not subjected to trauma) propagate into the alveolar bone (open arrow), while in teeth subjected to trauma from occlusion, the inflammatory infiltrate spreads directly into periodontal ligament (filled arrow)



2- Waerhaug's concept

He concluded from his analysis that angular bony defects and infra-bony pockets occur equally often at periodontal sites of teeth which are not affected by trauma from occlusion as in traumatised teeth

- In other words, **he refuted the hypothesis that trauma from occlusion played a role in the spread of a gingival lesion into the zone of co-destruction**
- The loss of connective attachment and resorption of bone around teeth are according to Waerhaug, exclusively the result of inflammatory lesions associated with subgingival plaque
- Waerhaug concluded that angular bony defects and infra-bony pockets occur when the subgingival plaque of one tooth has reached a more apical level than the microbiota on the neighbouring tooth, and when the volume of the alveolar bone surrounding the roots is comparatively large

Periodontal response to trauma from occlusion

Stages of tissue response to increased occlusal forces

Stage I- injury:

Changes in occlusal forces causes injury in this case

- **Repair attempted to restore the periodontium** and this occur if the forces diminished or tooth drifts away from forces
- **Remodeling occurs** if forces are chronic so the periodontium remodelled to cushion its impact. The ligament is widened at the expense of bone, resulting in angular bone defects without periodontal pockets and the tooth become loose

Varying degrees of pressure and tension create varying degrees of changes. The areas of the periodontium most susceptible to injury from excessive occlusal forces are the furcation areas

- Injury to the periodontium produce a temporary depression in mitotic activity and the rate of proliferation and differentiation of fibroblasts, in collagen and in bone formation. These return to normal levels after dissipation of the forces

- **Slight pressure**
 - Resorption of bone
 - Widening periodontal ligament space

- Blood vessels is increased in number and reduced in size

- **Slight tension**

- Periodontal ligament fibres thickening
- Apposition of bone
- Blood vessels enlargement

- **Greater pressure**

- Compression of fibres which produce areas of hyalinisation
- Injury to fibroblasts, C.T. cells leading to necrosis of areas of ligament
- Vascular changes: within 30 mins, impairment and stasis of blood flow occur; at 2 to 3h, blood vessels appear to be packed with erythrocytes which start to fragment; and between 1 and 7 days, disintegration of blood vessel walls and release of contents into the surrounding tissues occur, in addition to increase of tooth surface resorption
- Bone resorption

- **Greater tension**

- Widened periodontal ligament space
- Tearing of ligament and resorption of alveolar bone
- Haemorrhage and thrombosis

Stage II- repair

Repair is constantly occurring in the normal periodontium and trauma from occlusion stimulates increased reparative activity

- **Reparative activity includes formation of:**

- New C.T. cells and fibres, bone and cementum are formed in an attempt to restore the injured periodontium. Forces remain traumatic only as long as the damage produced exceeds the reparative capacity of the tissues

- Thin bone is reinforced with new bone (buttressing bone formation) which is either central buttressing (restores the bony trabeculae) or peripheral buttressing (occurs in the facial and lingual surfaces of the alveolar plate)

Repair occurs as long as reparative capacity exceeds traumatic forces

Stage III- adaptive remodelling

- Forces exceed repair capacity, periodontium is remodeled in an effort to create a structural relationship in which forces may no longer be injurious to the tissues, this results in thickened periodontal ligament, with no pocket formation and angular bone defect

- Following remodeling, stabilization of resorption and formation occurs and return to normal

Reversible traumatic lesions

- **Trauma from occlusion is reversible**
- **Repair or remodeling occurs if:**
 - Teeth can escape from force
 - Periodontium adapts to the force
- **Inflammation inhibits potential for bone regeneration-inflammation must be eliminated**
- **Tooth mobility:**
 - Occurs during injury stage (injured PDL)
 - Also occurs during repair/ remodeling(widened fibres)
 - Tooth mobility greater than normal but not considered pathologic tooth mobility is progressive in nature
- Fremitus (sensitive)
- Pain
- Tooth migration
- Attrition
- Muscle/joint pain
- Fractures, chipping

Radiographic signs of trauma from occlusion

1. Changes in shape of periodontal ligament space, bone loss
2. Thickened lamina dura
 - Lateral aspect of root
 - Apical area
 - Furcation areas
3. Vertical destruction of interdental septum
4. Root resorption, hypercementosis

- These changes do not necessarily indicate destructive changes because they may result from thickening and strengthening of the periodontal ligament and alveolar bone, constituting a favourable response to increased occlusal force

Treatment outcomes

Proposed by American Academy of Periodontology

1. Reduce/ eliminate tooth mobility
2. Eliminate occlusal prematurity's and fremitus
3. Eliminate parafunctional habits
4. Prevent further tooth migration
5. Decrease/stabilise radiographic changes

Therapy

- **Primary occlusal trauma**
 - Selective grinding
 - Habit control
 - Orthodontic movement
 - Inter-occlusal appliance
- **Secondary occlusal trauma**
 - Splinting
 - Selective grinding
 - Orthodontic movement

Unsuccessful therapy

- 1- Increasing tooth mobility
- 2- Progressive tooth migration
- 3- Continued client discomfort
- 4- Premature contacts remain
- 5- No change in radiographs/ worsening
- 6- Parafunctional habits remain
- 7- TMJ problems remain or become worse

Experiments carried out on humans as well as animals, have produced convincing evidence that neither unilateral forces nor jiggling forces, applied on teeth with a healthy periodontium, result in pocket formation or in loss of connective tissue attachment. Trauma from occlusion cannot induce periodontal tissue breakdown

- However, trauma from occlusion results in alveolar bone resorption, leading to increase tooth mobility, in presence of plaque may lead to progressive periodontal tissue loss
- In teeth with progressive plaque-associated periodontal disease, trauma from occlusion may act a co-factor in the destructive process
- **From clinical point of view**, this knowledge strengthens the demand for proper treatment of plaque associated periodontal disease
- This treatment will arrest the periodontal tissue destruction even if the occlusal trauma persists
- The treatment directed to trauma alone, however, i.e. occlusal adjustment or splinting, may reduce the mobility of the traumatised teeth and result in some bone regrowth
- But it will not arrest the rate of further breakdown of the supporting apparatus caused by plaque

References

- Clinical Periodontology and Implant Dentistry By Jan Lindhe
- Colour Atlas of Dental Medicine and Periodontology

Laser and its application in dentistry

Introduction

- Laser is an acronym for Light Amplification by Stimulated Emission of Radiation
- Nowadays, various laser systems are being using in dentistry
- Carbon dioxide (CO₂)
- Neodymium-doped: Yttrium-Garnet (Nd-YAG)
- Semiconductor diode lasers
- Erbium doped: Yttrium Aluminium- Garnet (Er:YAG)

In 1997, the food and drug administration cleared the first Er:YAG laser system, in the use for

- Preparation of dental cavities
- Incisions
- Excisions
- Vaporization
- Ablation
- Haemostasis of soft and hard tissues in the oral cavity

Properties of laser

Monochromatic: concentrate in a narrow range of wavelengths (one specific colour)

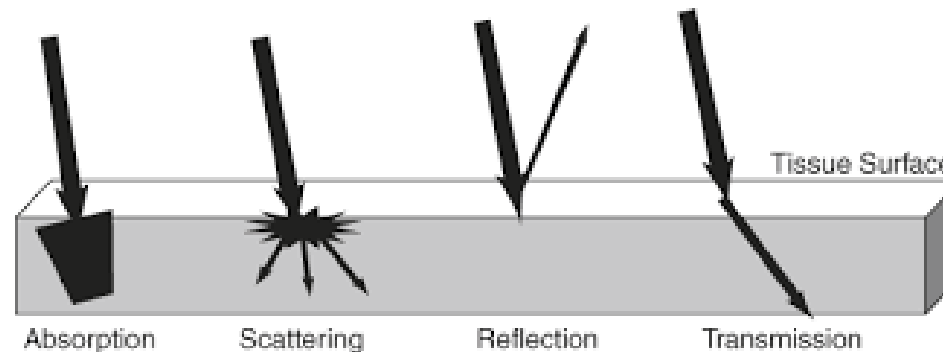
Coherent: all the emitted photons bear a constant phase relationship with each other in both time and phase

Collimated: perfectly parallel beam of directional light

Directional: a very tight beam which is very strong and concentrated

Laser effects on tissue

1. Scattering
2. Transmission
3. Absorption
4. Reflection



Source: Lalwani AK: CURRENT Diagnosis & Treatment in Otolaryngology - Head & Neck Surgery, 3rd Edition: www.accesssurgery.com
Copyright © The McGraw-Hill Companies, Inc. All rights reserved.

Classification of lasers

1- Classification based on light spectrum

2- Classification according to the material used

Classification according to material used

1- Gas

2- Liquid

3-Solid

Parts of laser machine

- Active medium/gain: gas, solid, liquid suspended in an optical cavity
- Power supply: external energy source, flash lamp/ electrical energy
- Optical resonator: mirrors for amplification
- Cooling system, control system, delivery system

Laser dentistry

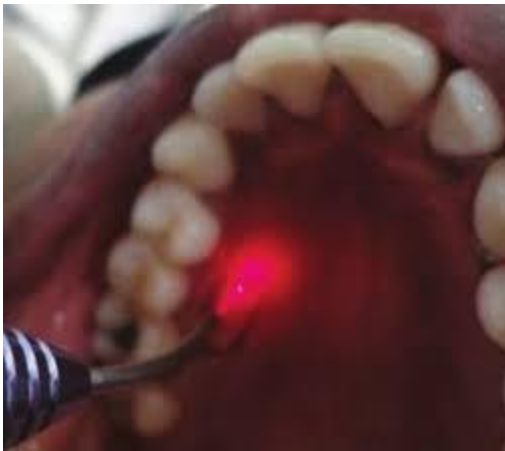(Less pain, less discomfort)

Uses of laser in Dentistry

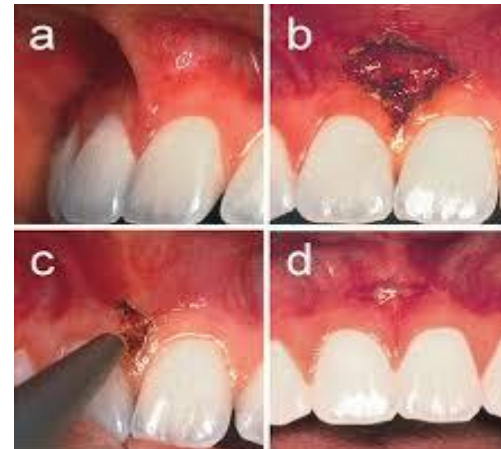- Periodontics
- Bone surgery
- Soft tissue surgery
- Root canal treatment
- Other uses

1- Periodontics

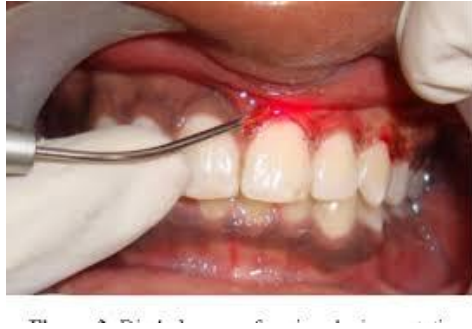Graft



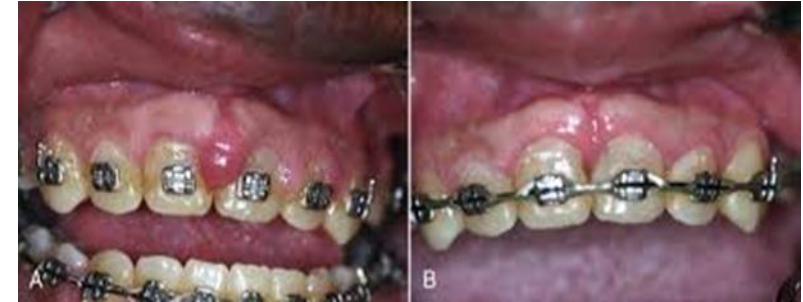Frenectomy



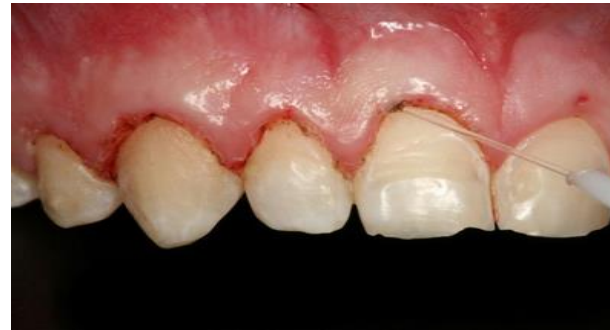- Depigmentation



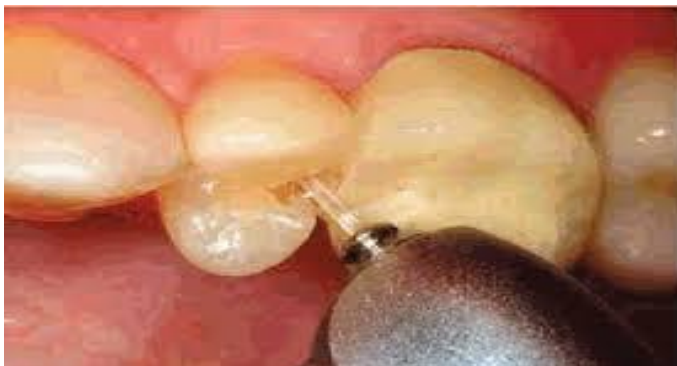Gingivectomy



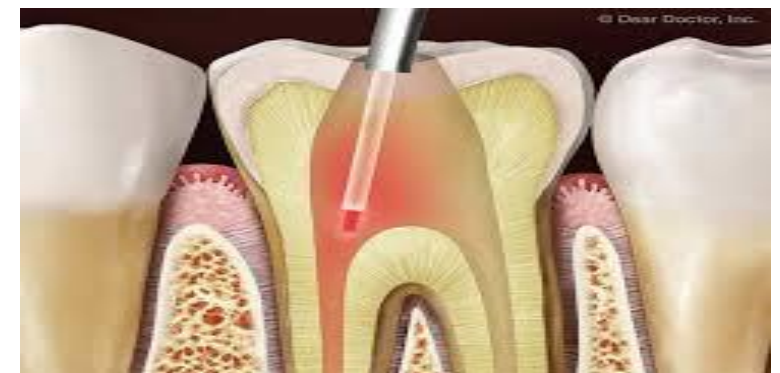- Crown lengthening



2- Hard tissue



3- Root canal



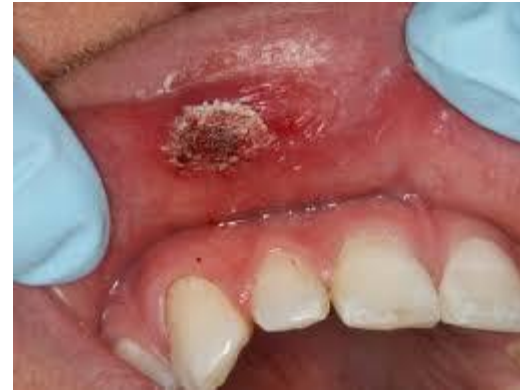Treatment of aphthous ulcer

Advantages of laser

1. Greater haemostasis
2. Bactericidal effect
3. Minimal wound contraction
4. Periodontal microsurgery benefit
5. Soft tissue surgery with CO₂ laser reduces the surgery time to about (1/4)

Disadvantages of laser

1. Requires precautions
2. Laser irradiation can interact with tissues even in the noncontact mode
3. Clinicians should be careful to prevent inadvertent irradiation to these tissues, especially to the eyes
4. Laser beams can be reflected by shiny surfaces of metal dental instruments, causing irradiation to other tissues
5. Previous laser systems have strong thermal side effects
6. Can not overlook the disadvantage of loss of tactile sensation



Precautions before and during irradiation

1. Prevent inadvertent irradiation (action in noncontact mode)
2. Protect the patient's eyes, throat and oral tissues outside the target site
3. Using wet gauze packs to avoid reflection from shiny metal surfaces
4. Ensure adequate high speed evacuation to capture the laser plume

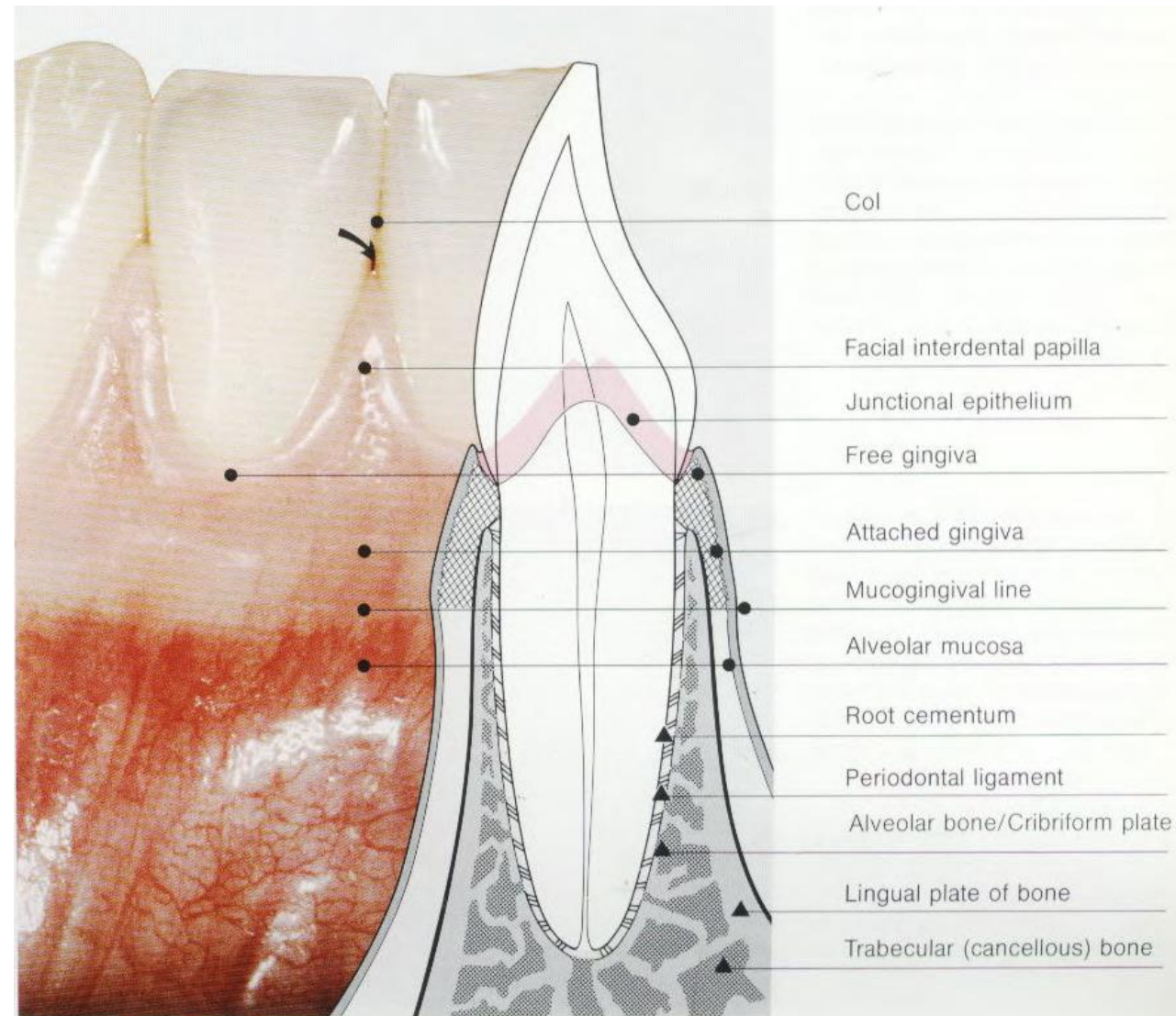
Benefits of laser

- The use of laser can decrease morbidity after surgery
- Reduces the need for anaesthetics
- Some of the risks of alternative electrosurgery procedures are avoided

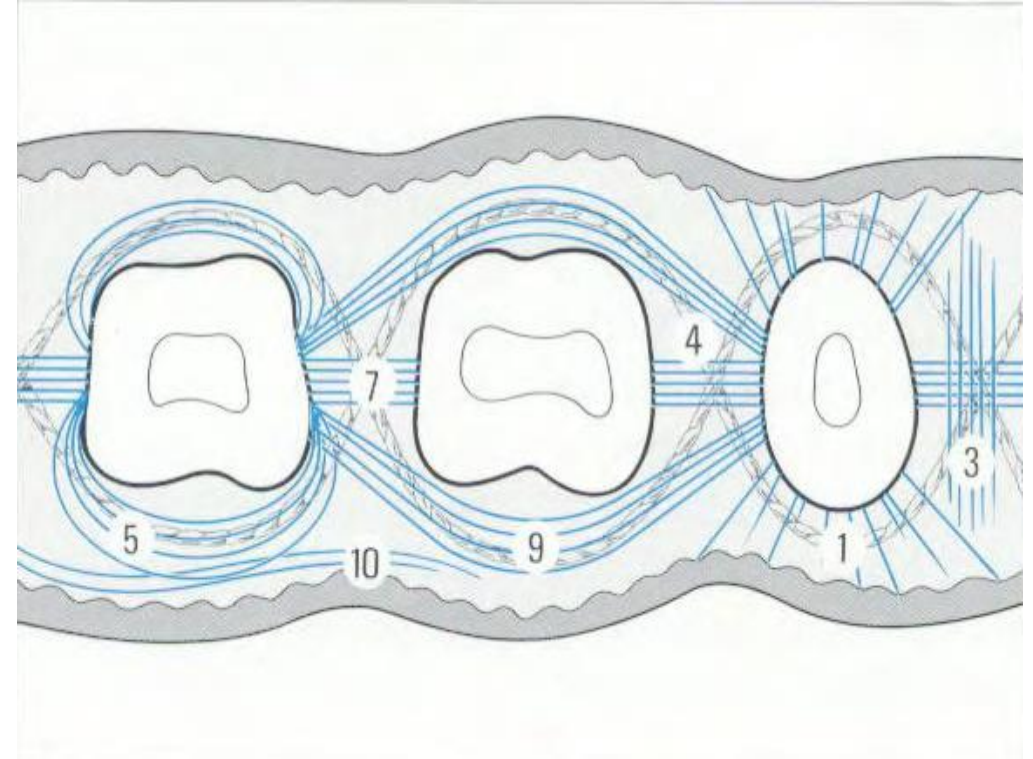
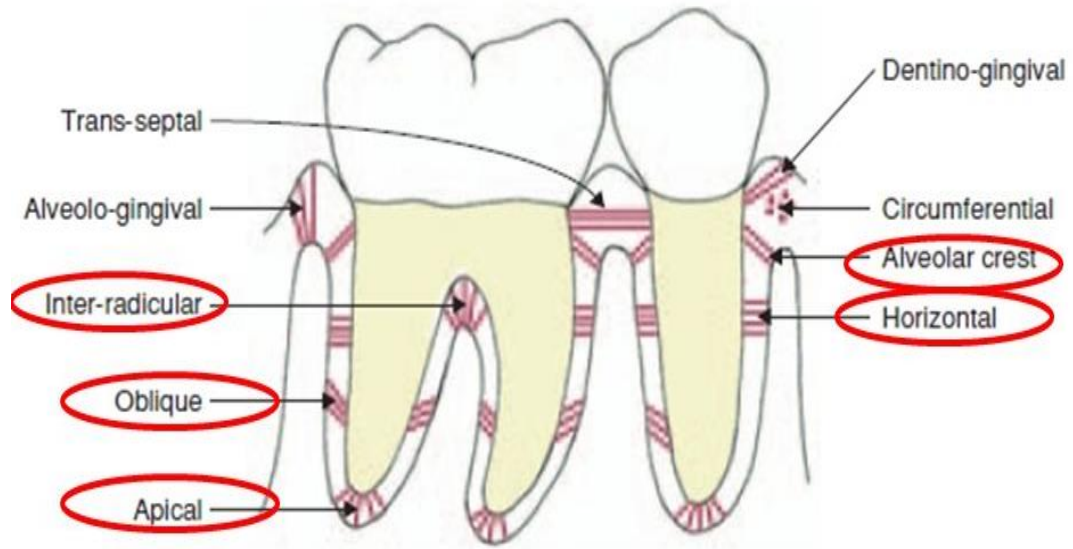
References

- Clinical Periodontology and Implant Dentistry By Jan Lindhe
- Colour Atlas of Dental Medicine and Periodontology

Periodontal tissue components

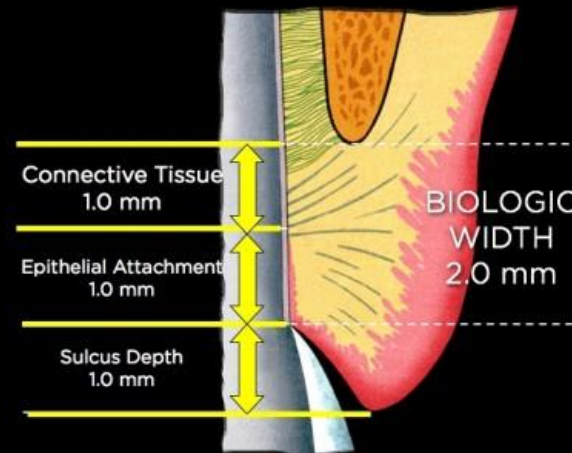


Periodontal ligaments



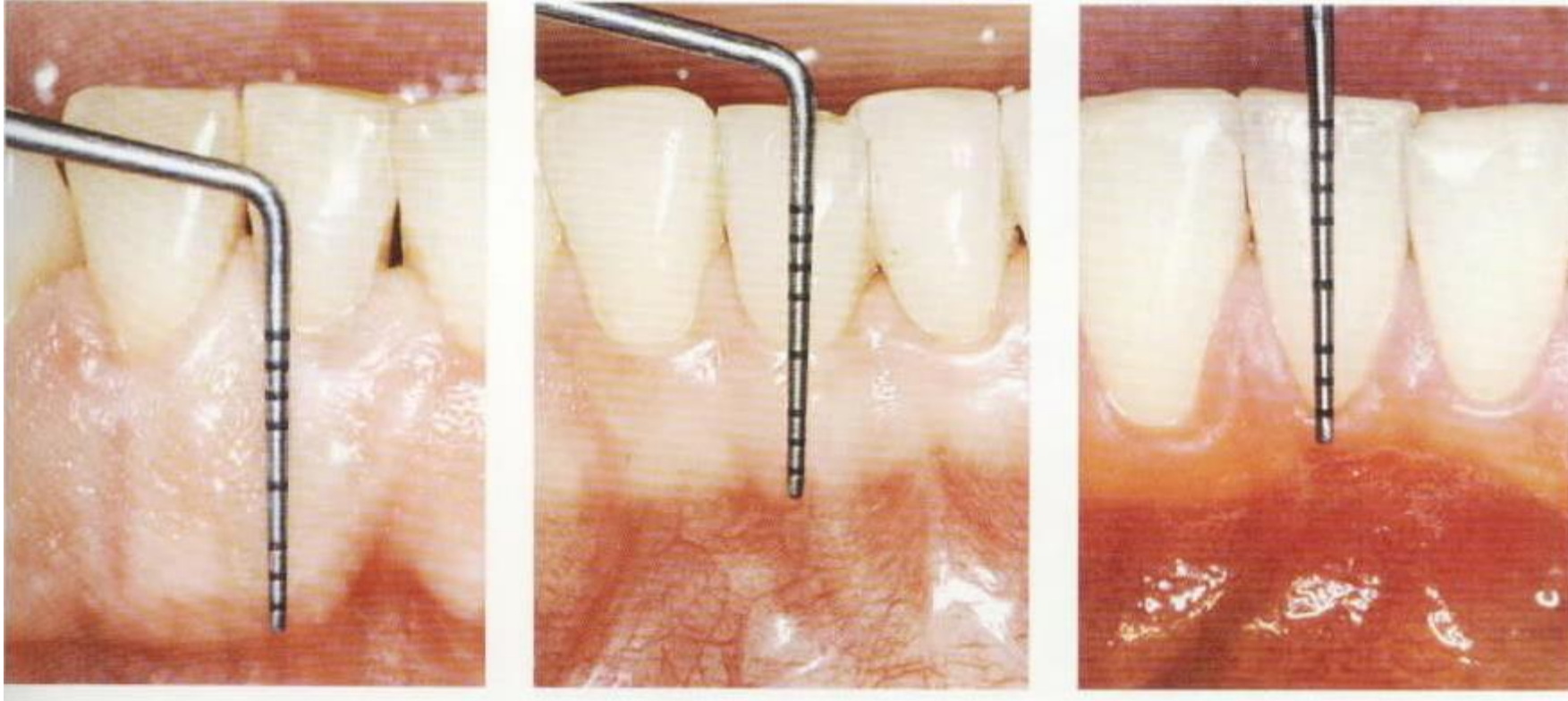
Biological width

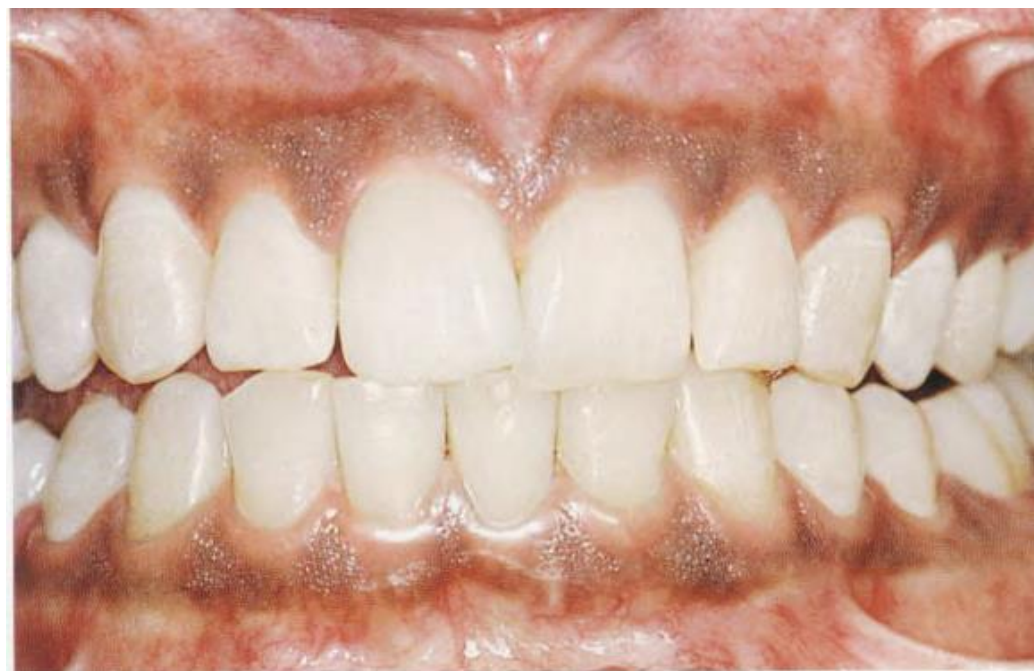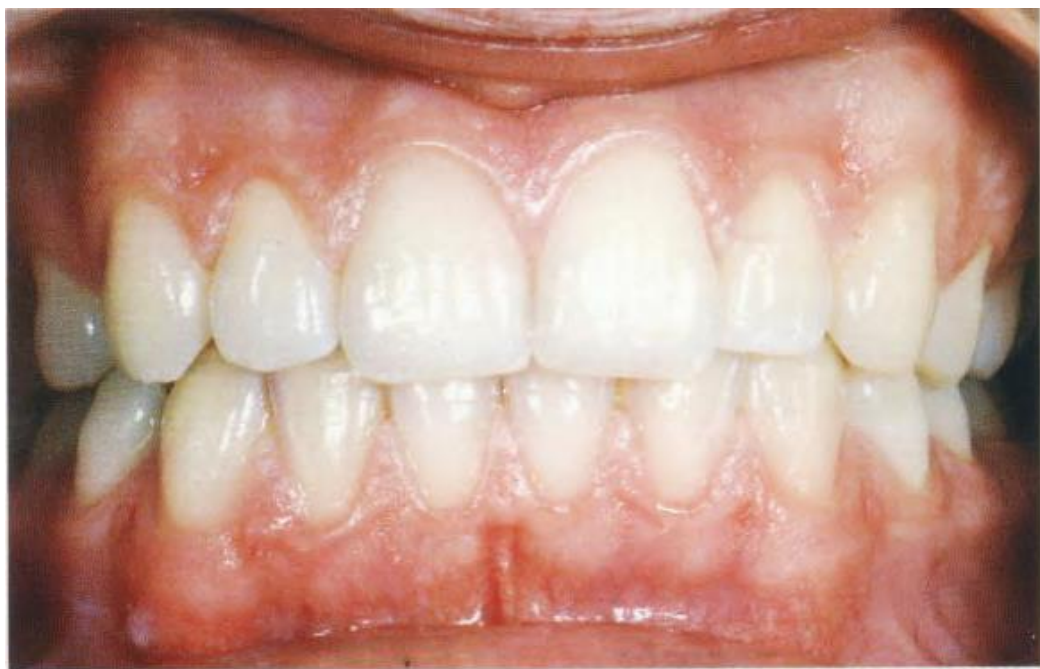Classic illustration of the average human attachment apparatus as described by Gargiulo, Wentz, and Orban in 1961



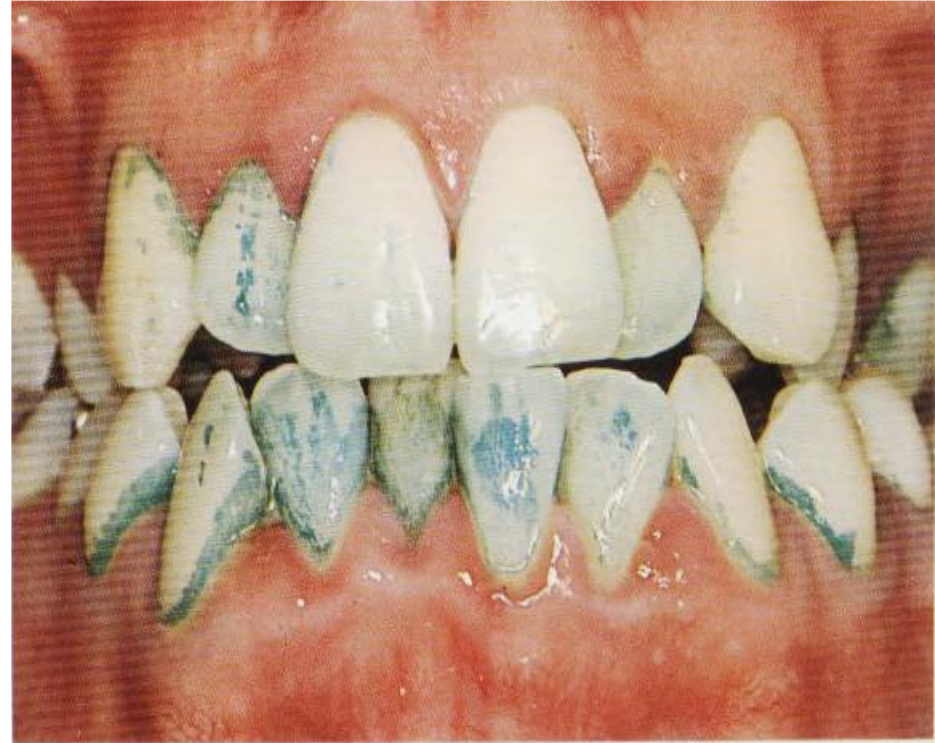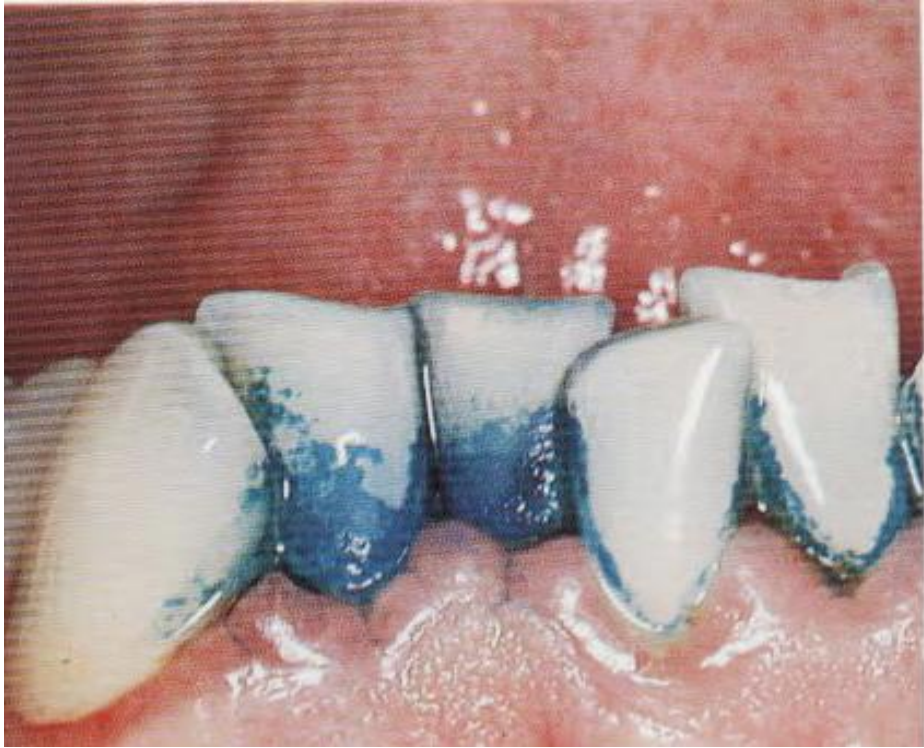The Connective tissue attachment and epithelial attachment form the "Biologic Width" averaging 2mm in most patients

Variation between individuals

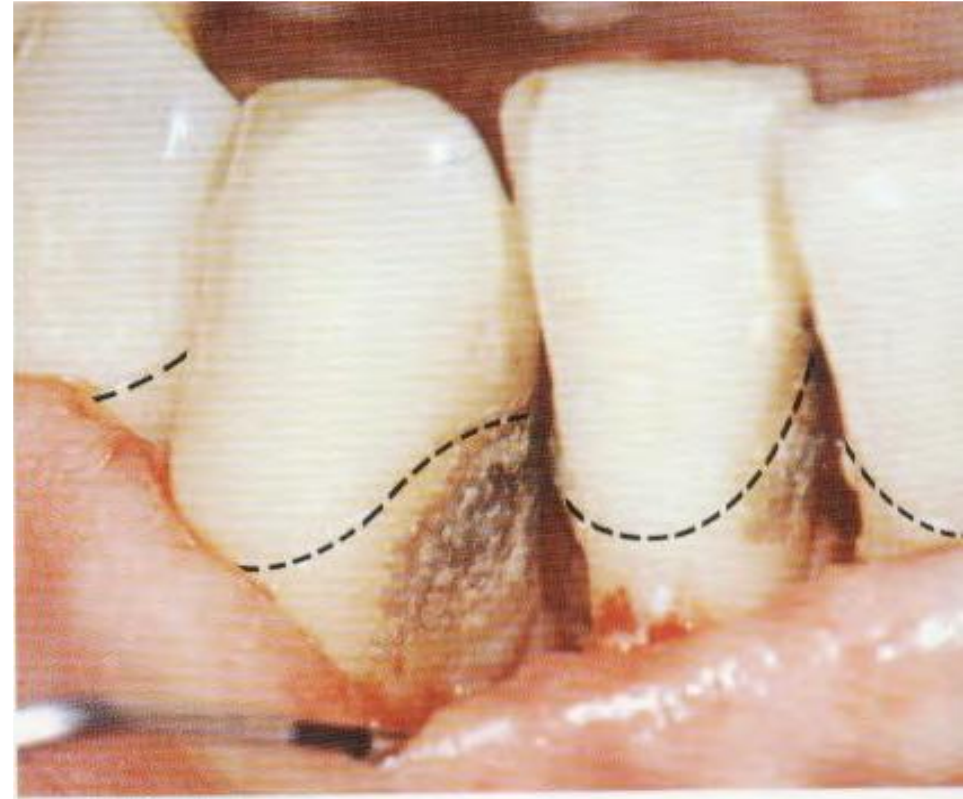
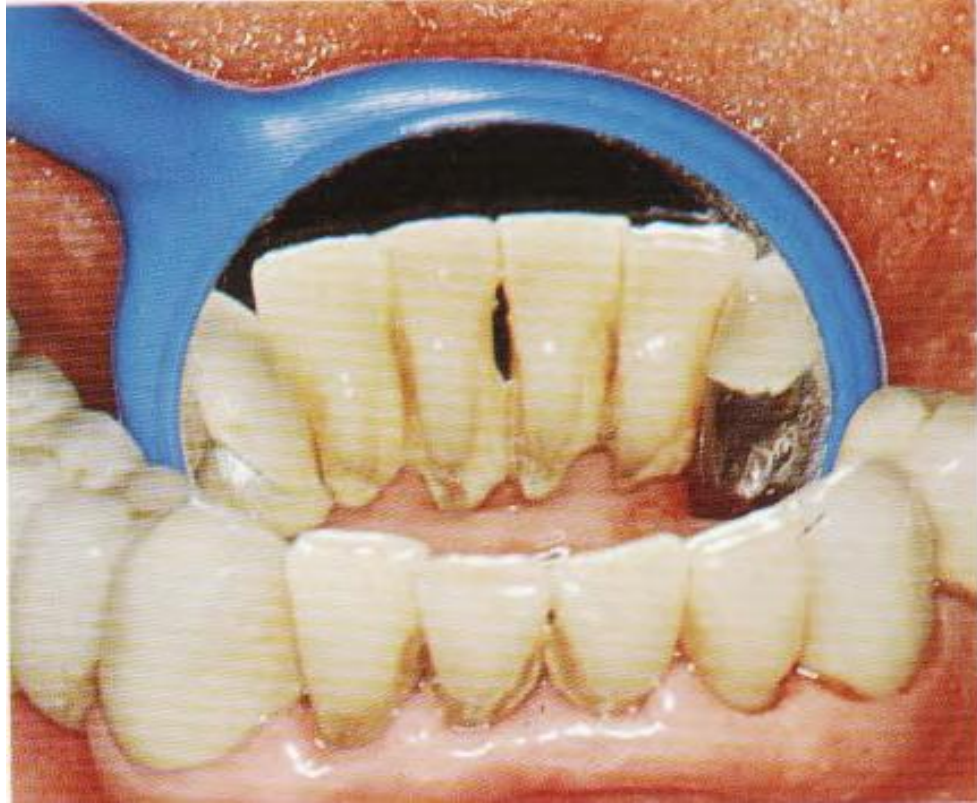



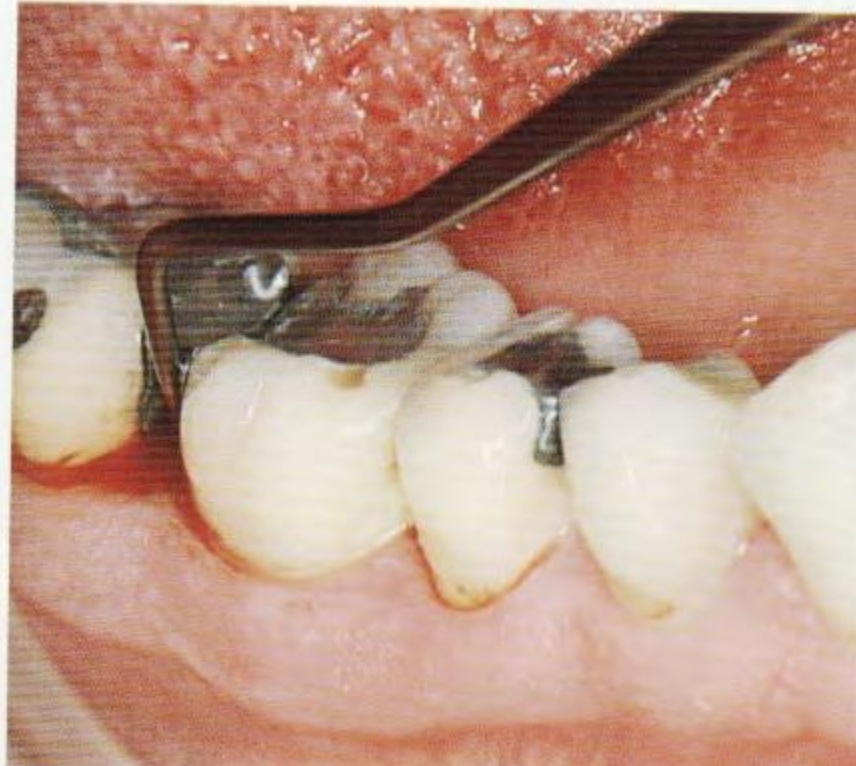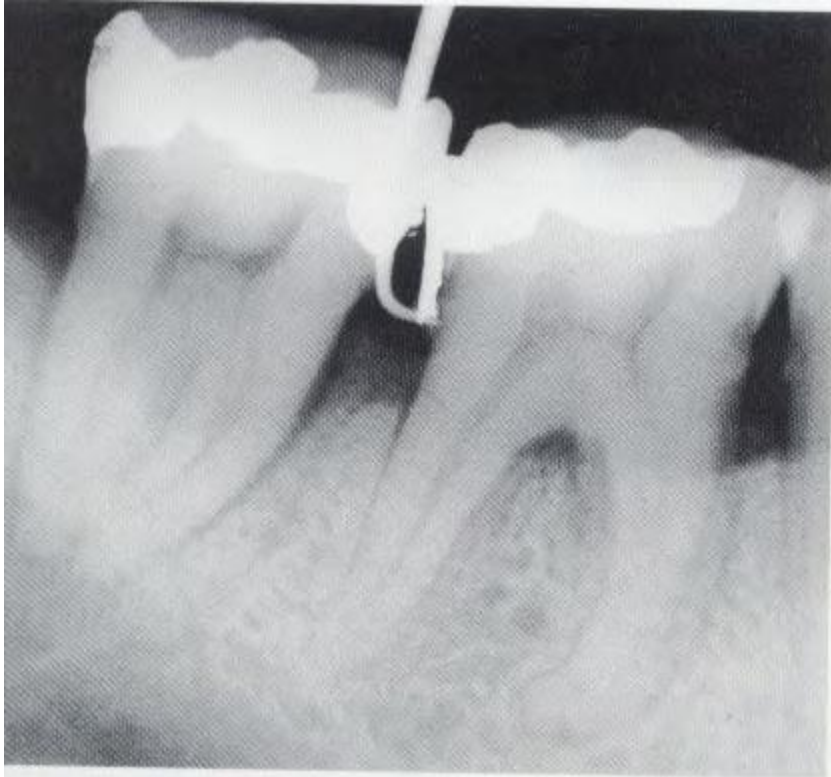
Plaque indicator



Dental Calculus

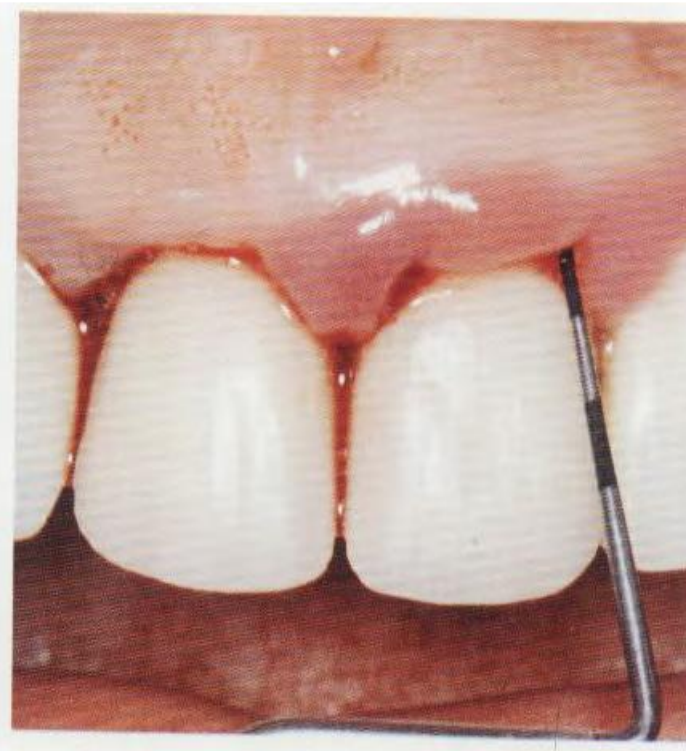
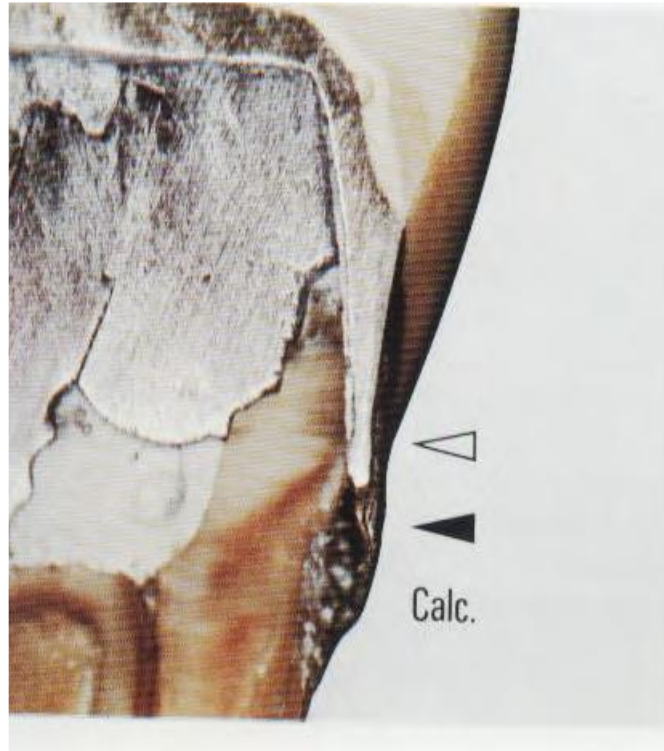
Plaque retentive factors



37 Amalgam restoration with overhang

Gross overhangs such as this, located subgingivally, invariably lead to plaque accumulation and to gingivitis (note hemorrhage). The plaque accumulated beneath an overhang changes in its composition: Pathogenic gram-negative anaerobes (e. g., *Bacteroides* species) increase markedly in number.



38 Crown margin overhang and open margins

Right: The cement that was used to cement this porcelain jacket crown has begun to extrude from the open margin. The massive retention of plaque between the crown and the prepared tooth led to severe gingivitis with establishment of a pathogenic bacterial flora.

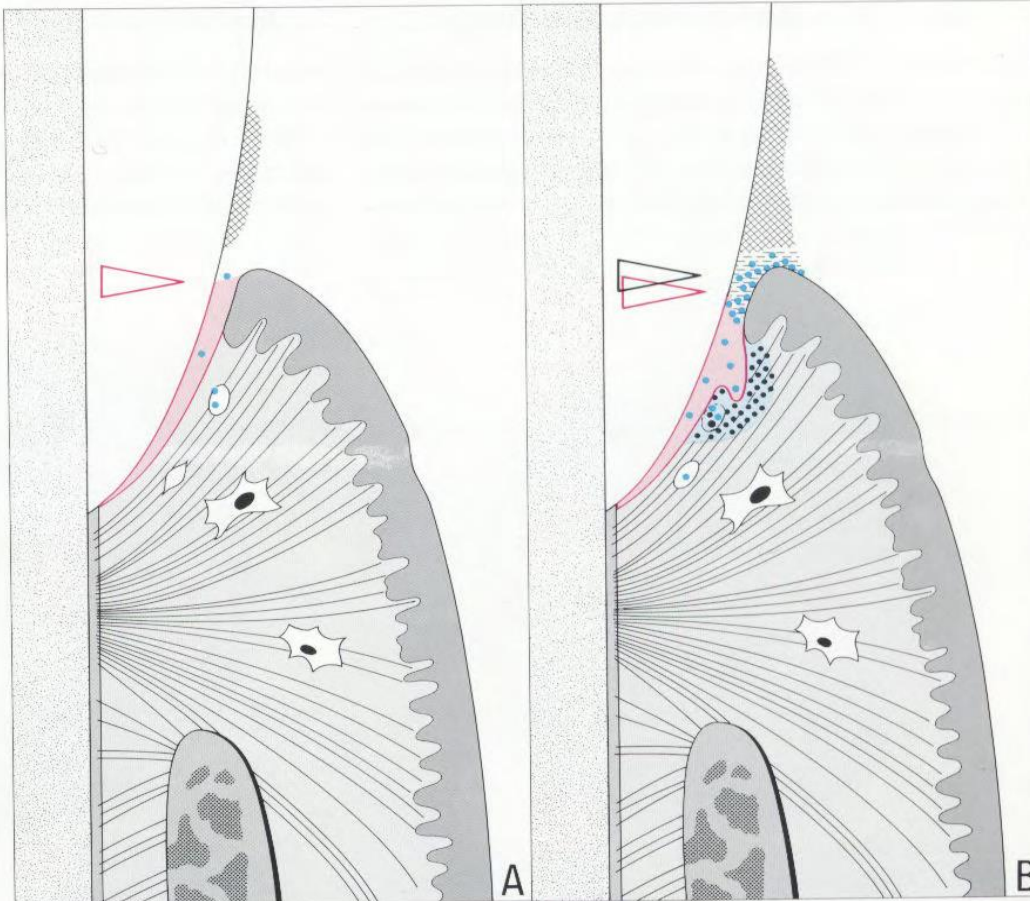
Left: Section through a porcelain-fused-to-gold crown with a margin that is both overhanging (arrows) and open. Darkly stained calculus is observed apical to the poor crown margin.

Pathogenesis of periodontal disease

Healthy gingiva → Gingivitis

45 Healthy gingiva (A)

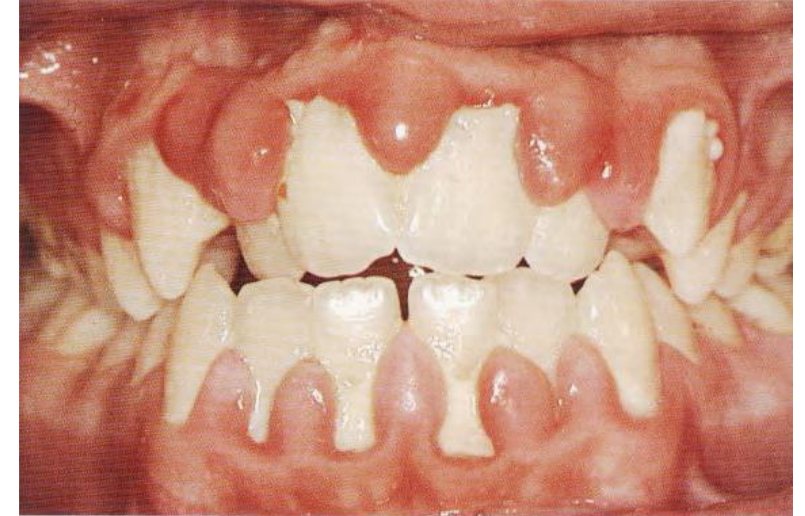
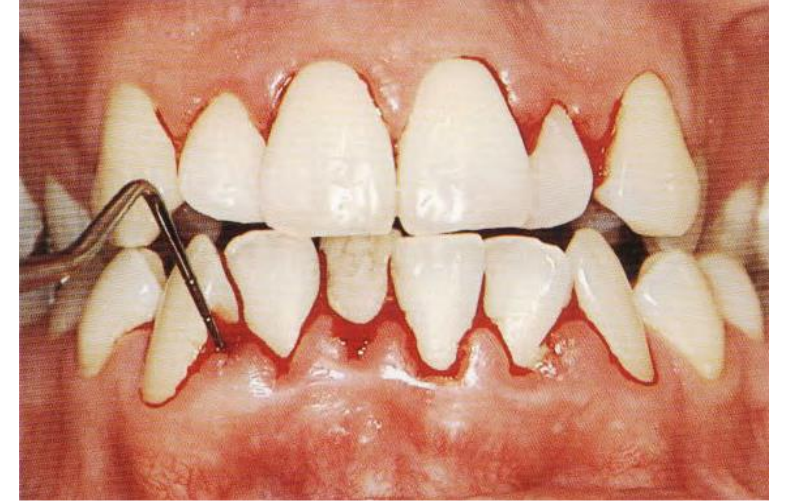
Absence of plaque or very little accumulation; normal junctional epithelium (pink); minimal sulcus depth (red arrow). A few PMNs (blue dots) transmigrate the JE in the direction of the sulcus bottom. Dense collagenous fiber system; intact fibroblasts.



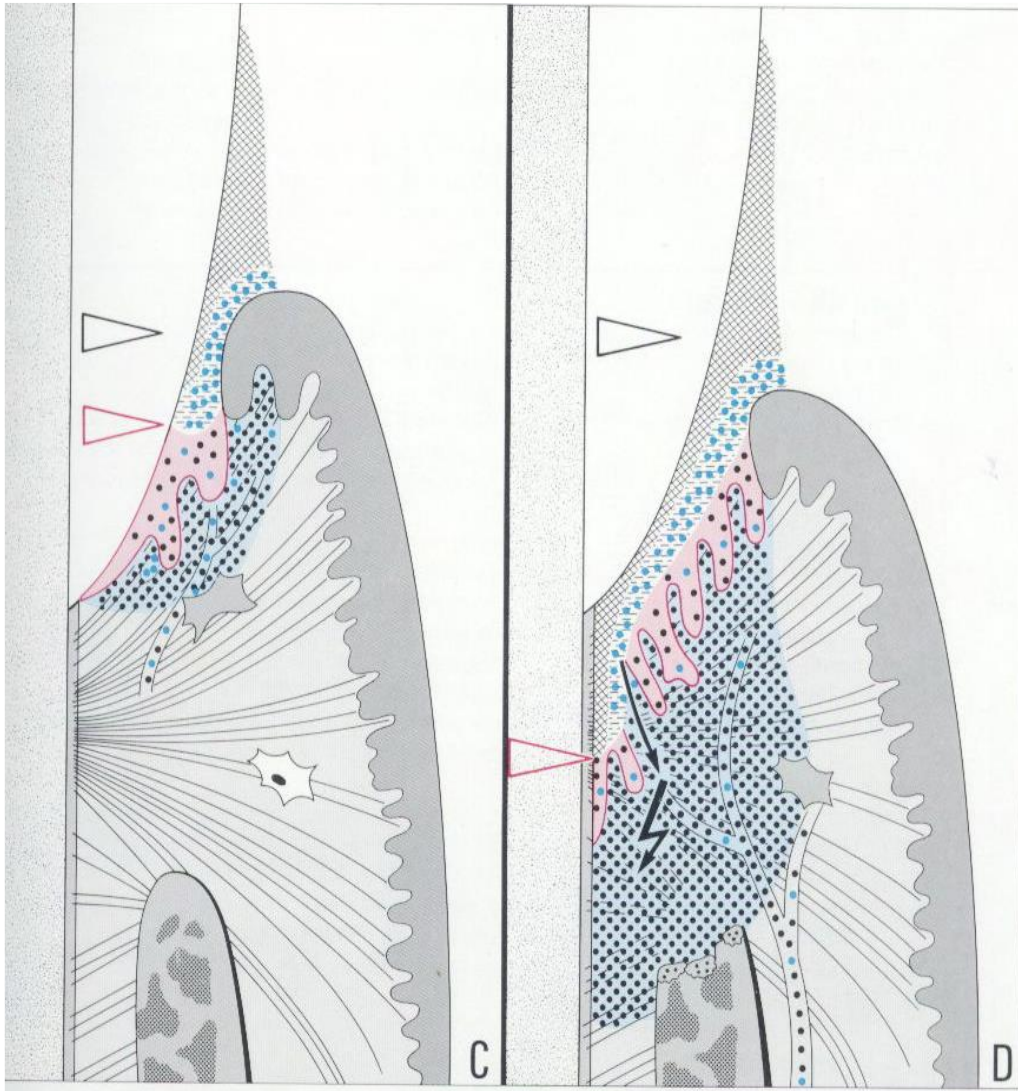
46 Initial/Early gingivitis (B)

Early plaque accumulation. In the *initial* lesion, increased transmigration of PMNs (blue dots) within the JE.

As the *early* lesion develops, the PMNs create within the slightly deepened sulcus (red arrow) a wall against the plaque bacteria. A lymphocytic infiltrate (black dots) occurs in the subepithelial tissues.



Gingivitis → Periodontitis



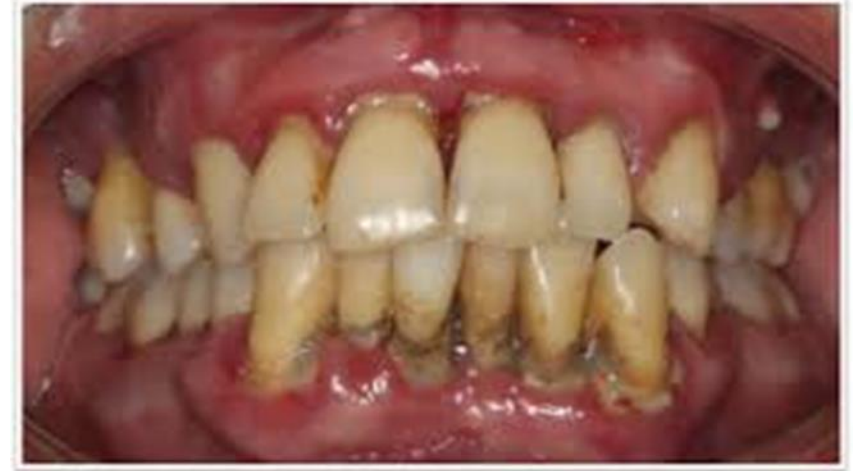47 Established lesion (C)

The gingiva responds to a massive accumulation of plaque. All of the characteristics of gingivitis are manifest but may be more or less pronounced both clinically and histologically. The junctional epithelium, i.e., the epithelial attachment, may actually be displaced somewhat apically as a consequence of the advancing front of accumulating plaque, resulting in the formation of a gingival pocket (distance between red and black arrows). Nevertheless, at this stage there is no loss of connective tissue attachment. The differentiated inflammatory infiltrate protects the deeper structures of the periodontium.

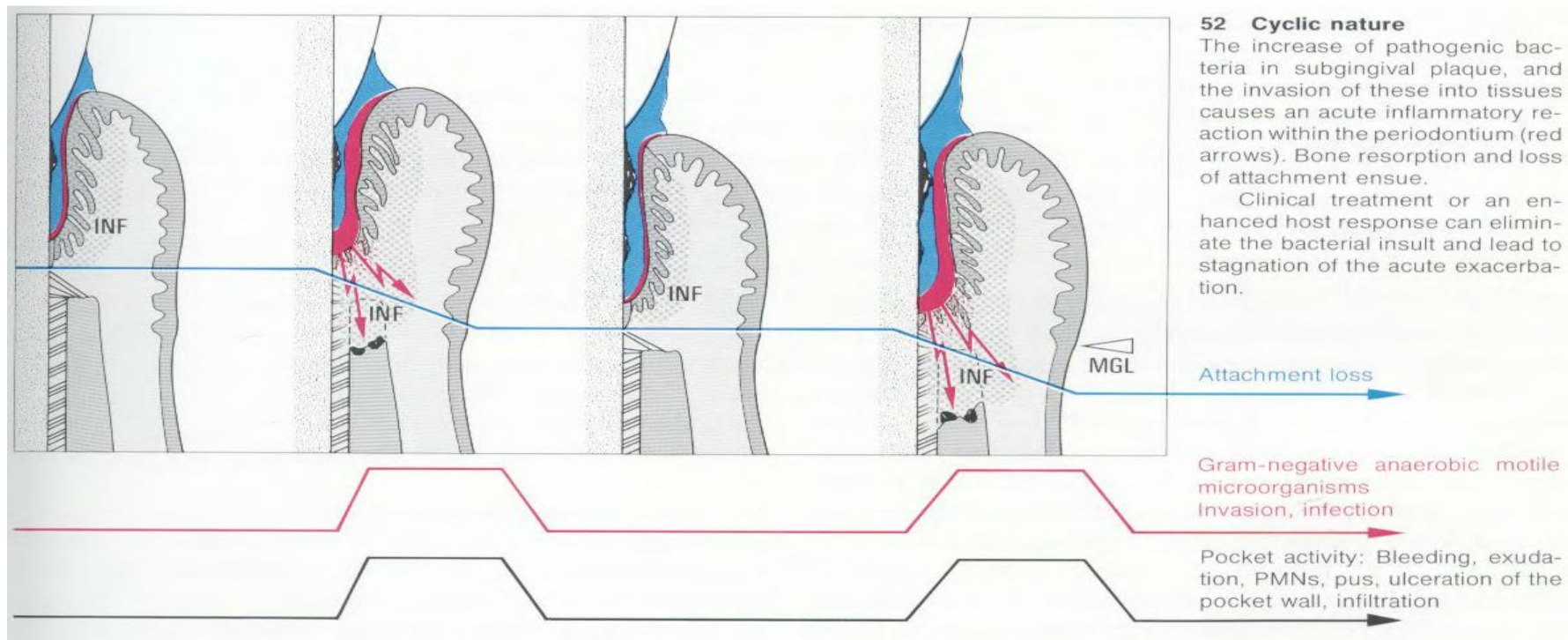
48 Periodontitis (D)

The most important histological differences between gingivitis and periodontitis are bone resorption, apical proliferation and ulceration of the junctional (pocket) epithelium (red arrow indicates base of pocket), and progressive loss of connective tissue attachment.

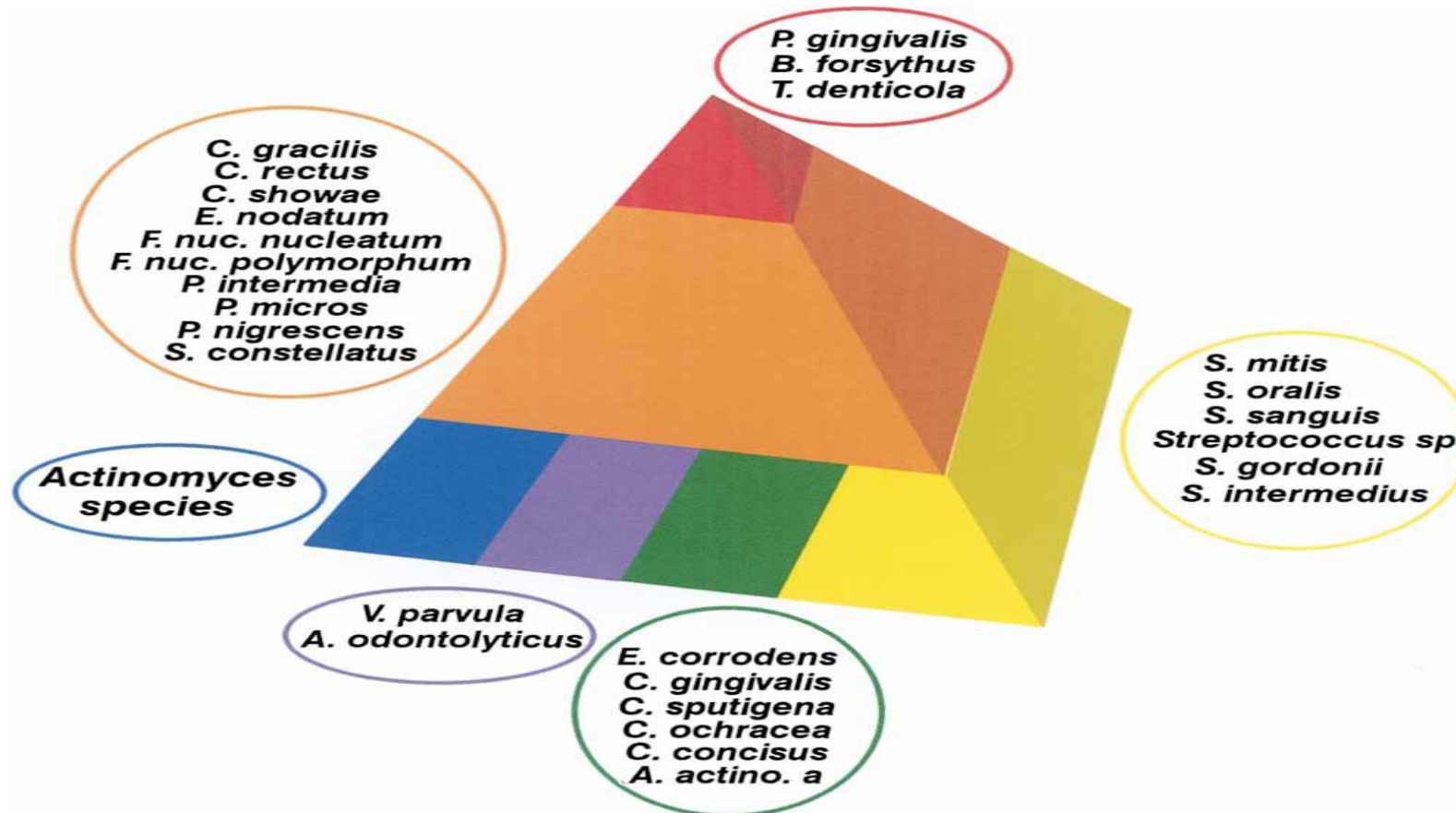
In acute phases there may be bacterial invasion of the tissue, with resultant micro- or macro-abscesses.



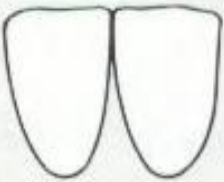



Cyclic Nature of Periodontitis – Attachment Loss – Bone Resorption




Bacterial plaque biofilm



Plaque index

Score 0	No plaque	
1	Thin film of plaque at the gingival margin, visible only when scraped with an explorer	
2	Moderate amount of plaque along the gingival margin; interdental space free of plaque; plaque visible with the naked eye	
3	Heavy plaque accumulation at the gingival margin; interdental space filled with plaque	



Gingival index





Grade 0	normal gingiva, no inflammation, no discoloration, no bleeding
1	mild inflammation, slight color change, mild alteration of gingival surface, no bleeding
2	moderate inflammation, erythema, swelling, bleeding on probing or when pressure applied
3	severe inflammation, severe erythema and swelling, tendency toward spontaneous hemorrhage, some ulceration

59 Gingival Index (GI)

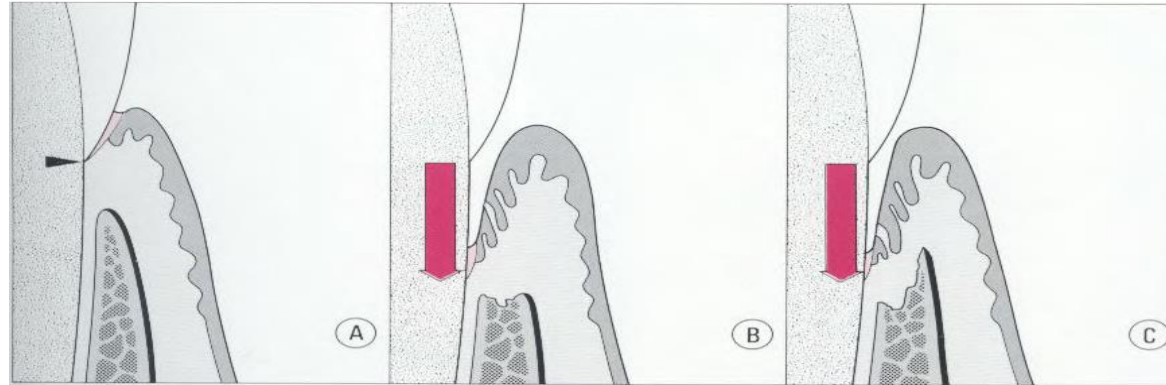
This index is used worldwide in epidemiological studies and scientific investigations. The GI scores gingival inflammation on the facial, lingual and mesial surfaces of all teeth. The symptom of bleeding comprises a score of 2.

The GI is recommended for epidemiological studies. It is less applicable for individual patients because the differences between the scoring levels are too gross.

Gingival recession

Table 1 Miller's classification of recession defects		
Class I		Recession that does not extend to the mucogingival junction with no periodontal bone loss in the interdental areas
Class II		Recession that extends to or beyond the mucovingival junction, with no interdental bone loss
Class III		Recession that extends to or beyond the mucogingival junction, with some periodontal attachment loss in the interdental area or malpositioning of the teeth
Class IV		Recession that extends to or beyond the mucogingival junction, with severe bone and/or soft-tissue loss in the interdental area and/or severe malpositioning of the teeth

Types of bone loss in Periodontal disease



122 Types of pockets

A. Normal sulcus

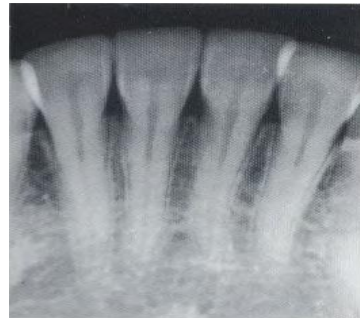
Apical termination of the JE is at the cemento-enamel junction (arrow).

B. Suprabony pocket

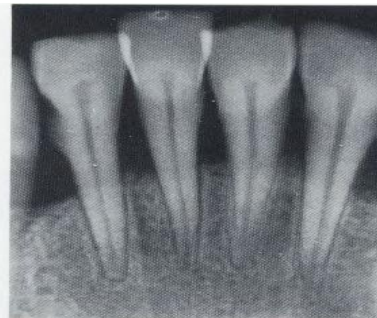
Proliferating pocket epithelium. A remnant of junctional epithelium persists (pink).

C. Infrabony pocket

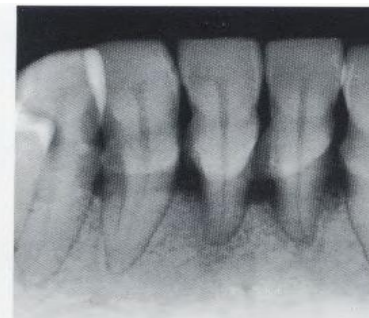Extends beyond alveolar crest.



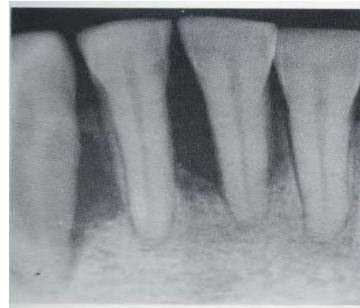123 No attachment loss, normal alveolar septa (left)
Lamina dura remains intact.



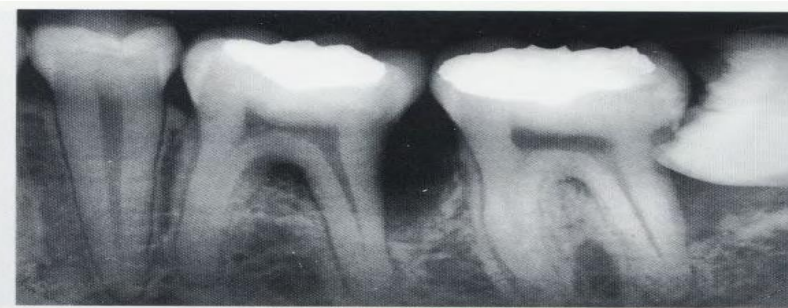124 Horizontal bone loss (middle)
Up to 50% loss of interdental septal bone.



125 Severe horizontal bone loss (right)
Up to 80% bone loss. Heavy calculus accumulation.



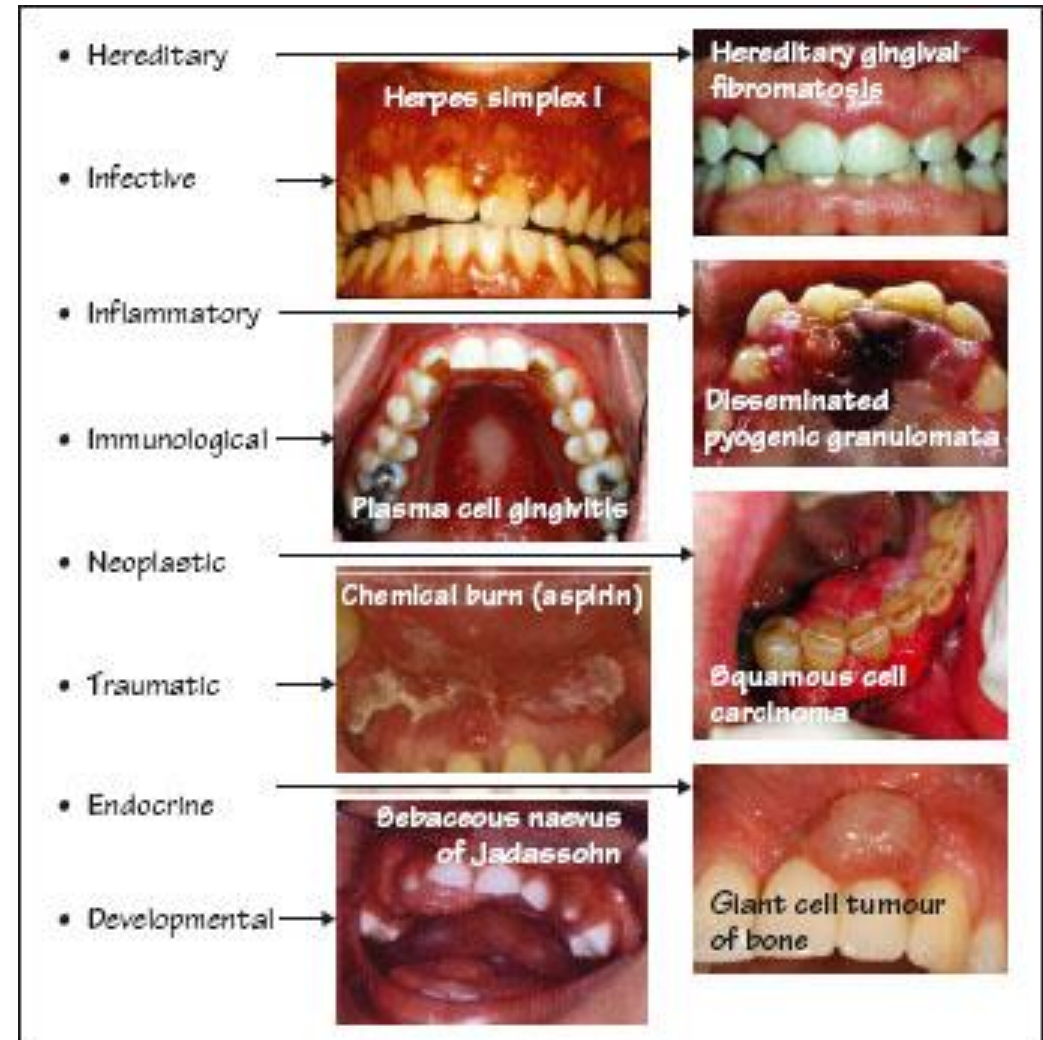
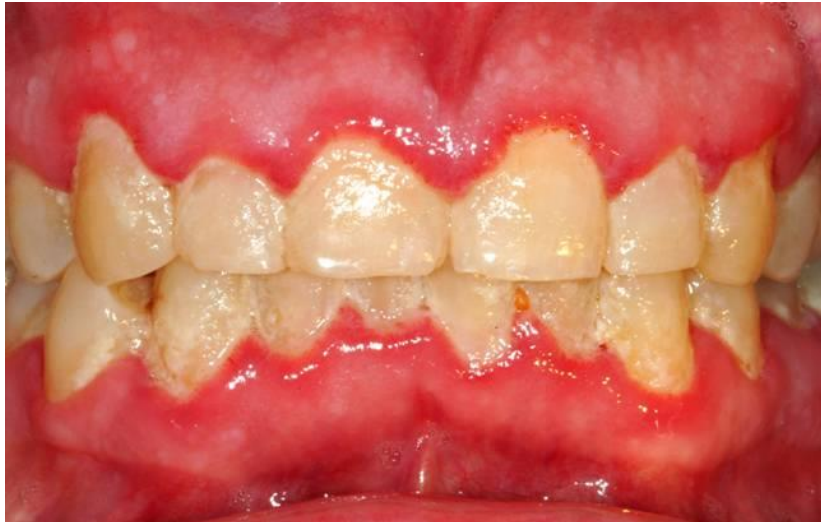126 Vertical bone loss – Craters (left)
Irregular pattern of destruction of alveolar septa. Mesial to the cuspid, evidence of undermining or cyst formation.



127 Vertical bone loss – Furcation involvement (right)
Severe bone loss distal to the first molar. On the same tooth the interdental bone (furcation) is also involved in the destruction.

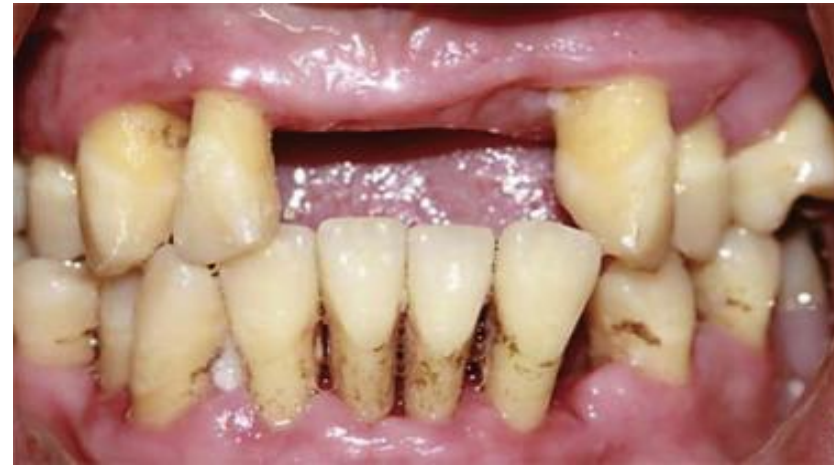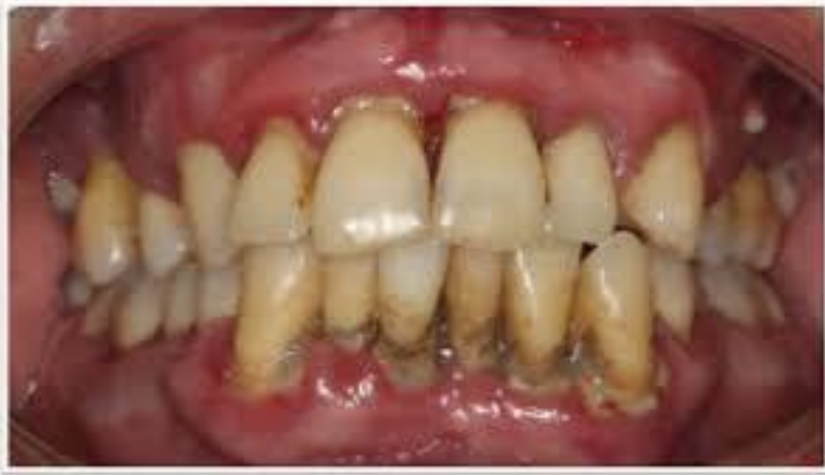Classification of gingival disease

1. Plaque induced gingivitis
2. Non plaque induced gingivitis



Classification of periodontal disease



- Chronic periodontitis (adult periodontitis) localized or generalised
- Aggressive periodontitis (early onset, juvenile periodontitis) localised or generalised



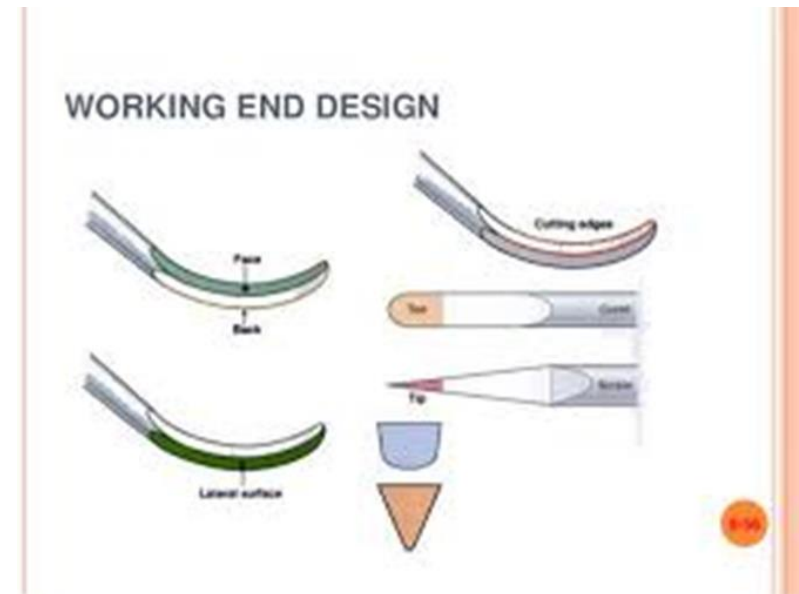
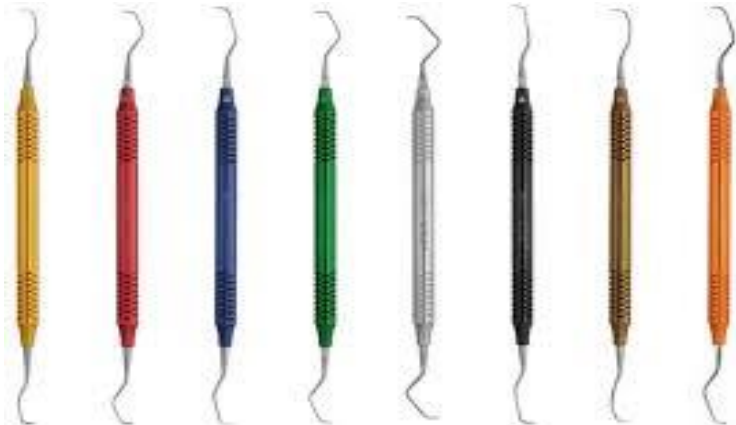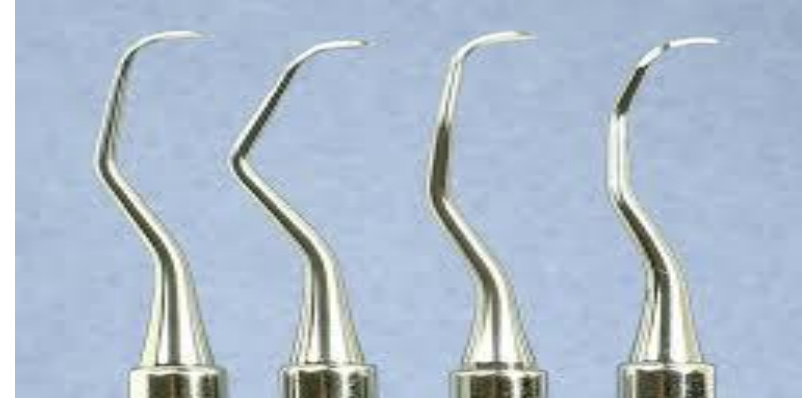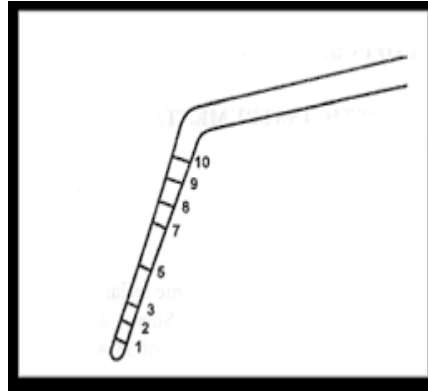
What are the aims of periodontal treatment?

1. Reduction of gingivitis (bleeding on probing, halitosis).
2. Reduction of pocket depth.
3. Cessation (stopping) of pain
4. Individual satisfactory in terms of aesthetic and function

Periodontal treatment can be achieved through:

1. Patient motivation  ??? ???
2. Patient instruction  ??? ???
3. Scaling and polishing
4. Elimination of any plaque retentive factors (defective and overhang fillings, crowns)
5. Orthodontic treatment and occlusal therapy.

Some periodontal instruments



References

- Clinical Periodontology and Implant Dentistry By Jan Lindhe
- Colour Atlas of Dental Medicine and Periodontology

Introduction

- Periodontal disease is an infectious disease process that involved by inflammation. It involves the structure of periodontium, causing a breakdown, resulting in loss of tissue attachment and destruction of the alveolar bone

Prevalence of periodontal disease

- Periodontal disease is leading to tooth loss in adults
- In the USA for example 75% of the population has different form of periodontal disease, and most of them are unaware of the disease
- Very high percentage of adults and children, having calculus on their teeth
- Early detection and treatment of this disease can save the teeth for long life

Types of periodontal disease

Gingivitis: is a reversible inflammation of the gingival tissue, limited to epithelium and connective but not the alveolar bone. It is characterised by redness, swelling and tendency to bleeding.

- It is painless and often unrecognised until the dental professional emphasises its importance
- Can be improved by daily practice of proper oral hygiene

Gingivitis are also associated with:

Puberty, pregnancy and some medications

Periodontitis: inflammation of teeth supporting tissues, which extends from the gingiva into the connective tissue and the alveolar bone, leading to bone destruction and connective tissue loss.

Signs and symptoms of periodontal disease:

- Redness, swelling, bleeding on probing, brushing and flossing
- Loose and separating teeth
- Pain or pressure on chewing
- Pus discharge from the sulcus
- However, there is no sharp pain

Importance of periodontal disease diagnosis

- To determine the disease presence
- To identify its type
- Extension
- Severity
- Distribution
- Underlying pathological process

First visit

- Overall patient evaluation
- Medical history
- Dental history
- Radiographic survey whether peri-apical or OPG (orthopantomogram)

Overall patient evaluation

-Mental and emotional

Attitude

-Physiological age

Medical history

- Systemic diseases
- Conditions or behavioural factors may affect the periodontal disease
- Oral infection which may affect severity of some systemic disease
- It also includes:
 1. If the patient under medical care
 2. Hospitalisation
 3. Medications
 4. Medical problems
 5. Occupational disease
 6. Abnormal bleeding

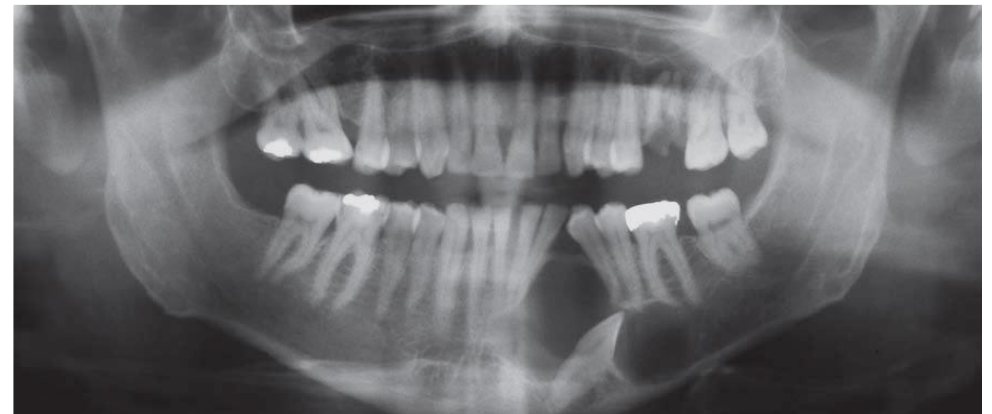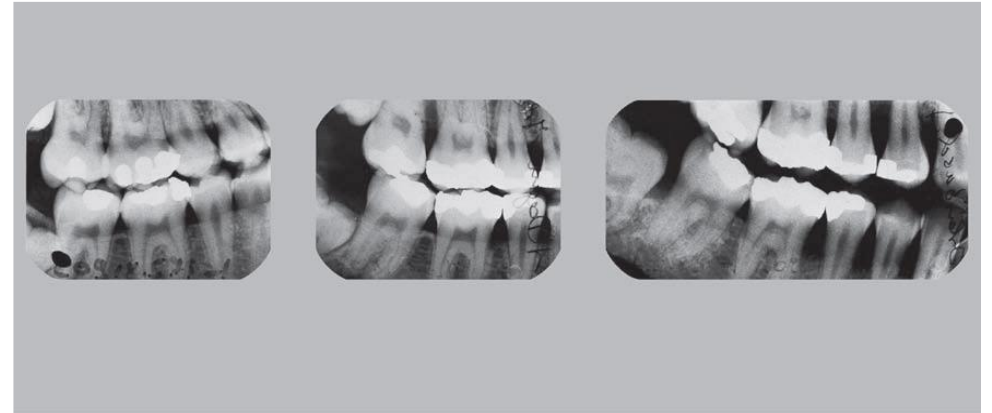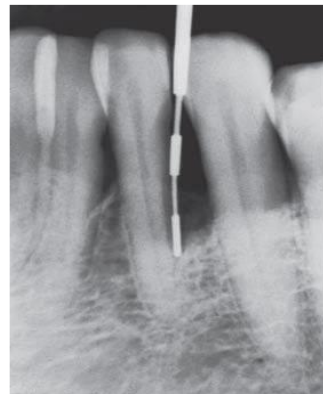
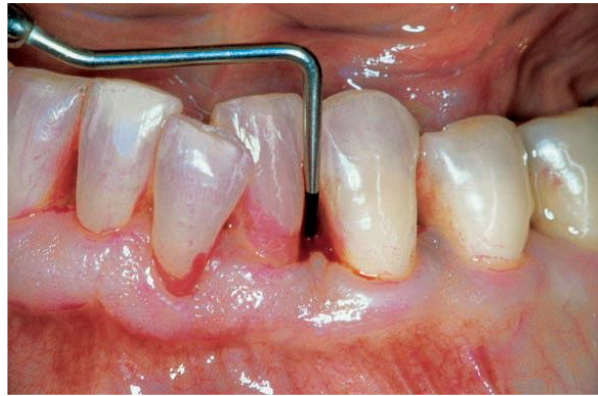Dental history

- What is the current illness
- Dental history includes:
 - Dental visit
 - Oral hygiene
 - Orthodontic treatment
 - Pain
 - Bleeding gingiva
 - Teeth mobility
 - Dental habits
 - Previous history of periodontal problems

Intra-oral radiographic survey

- Peri-apical and posterior bitewing films
- Panoramic radiograph

Both are helpful in detection of developmental anomalies, pathological lesions of teeth and alveolar bone level.



Oral hygiene

- Plaque index (Silness and loe)
- Disclosing agent
- Oral malodour: halitosis
- Plaque does not always related to the severity of the disease as in aggressive periodontitis

Oral cavity Examination

-Examination of lip, floor of the mouth, tongue, palate and oropharyngeal region

Lymph node examination

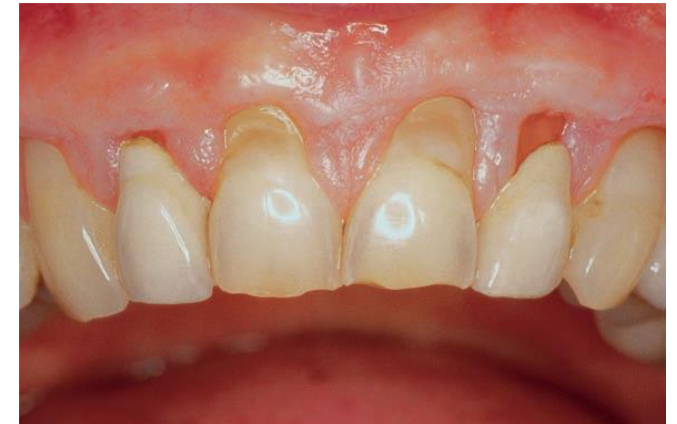-Whether enlarged, palpable, tender or immobile.

-Acute necrotising ulcerative gingivitis (ANUG), primary herpetic gingivostomatitis and acute periodontal abscess

Check for

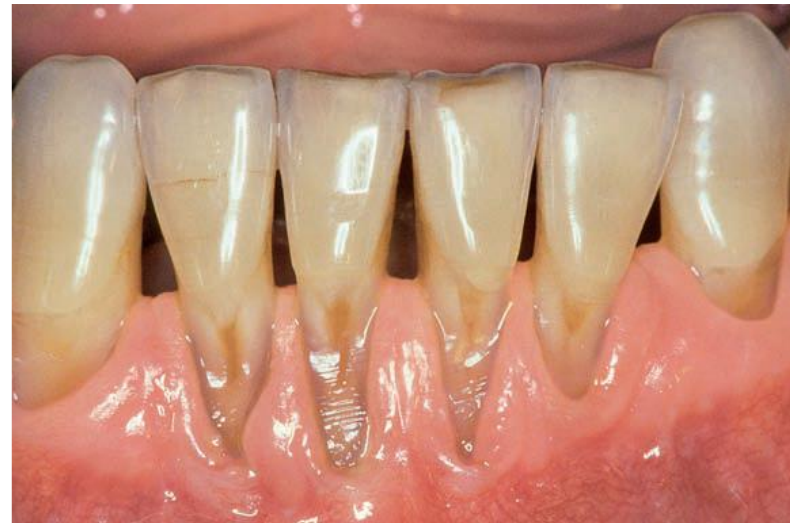Attrition: tooth to tooth functional contact, leading to occlusal wear and short crowns

Abfraction: occlusal loading surfaces causing mechanical microfractures and tooth substances loss at the cervical area



Abrasion: Saucer-Shaped defects due to mechanical effect of tooth brush, pipe smoking....etc

-Erosion: wedge-shaped defect on the cervical part of the enamel, dentine and cementum of teeth



Dental stain

- Pigmented deposits
- sources

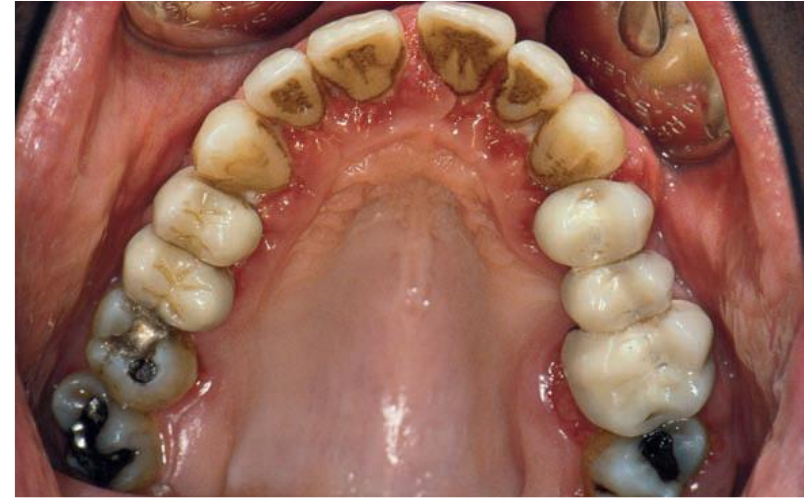Hypersensitivity: exposed root surfaces

Proximal contact relationship

By clinical observation and dental floss

Tooth mobility

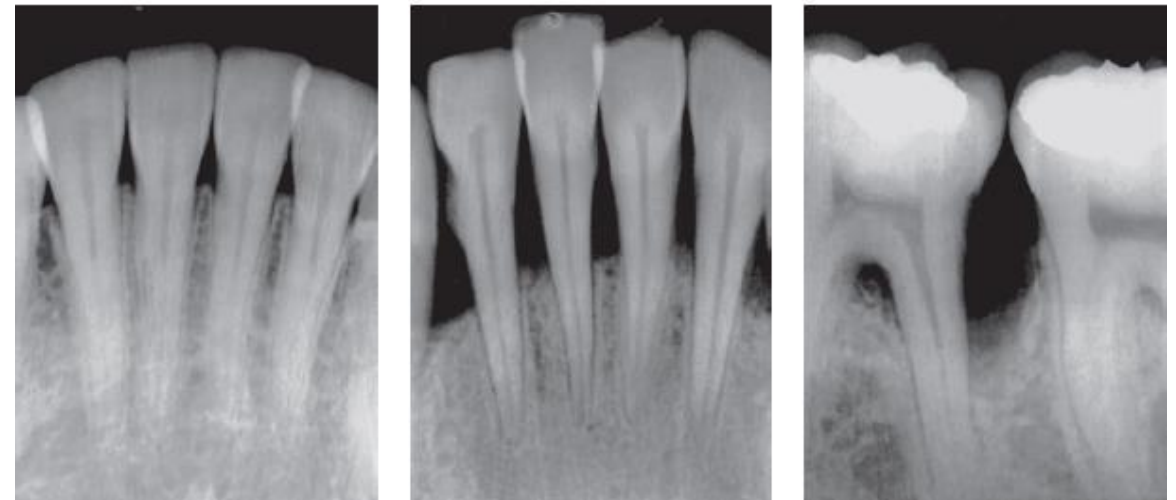
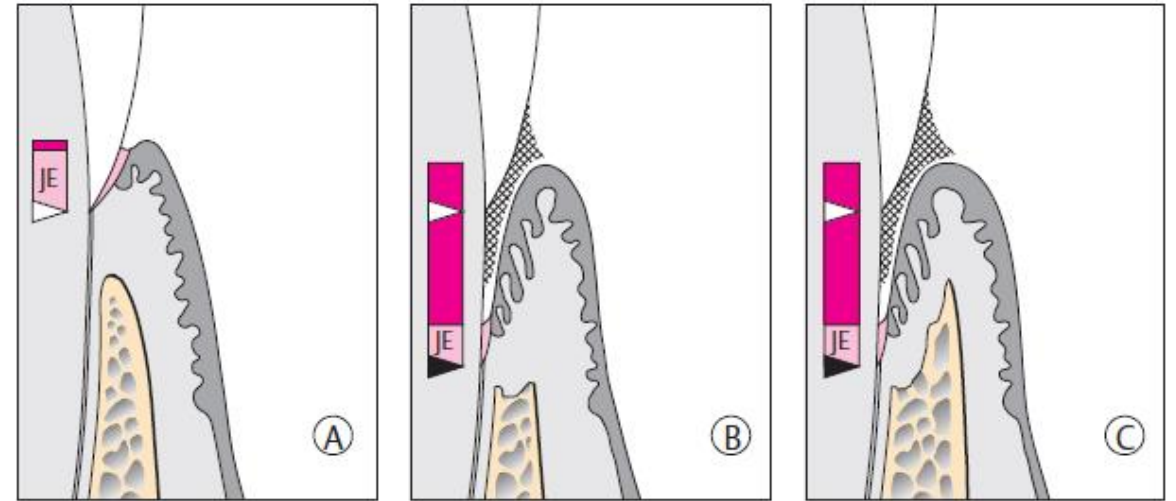
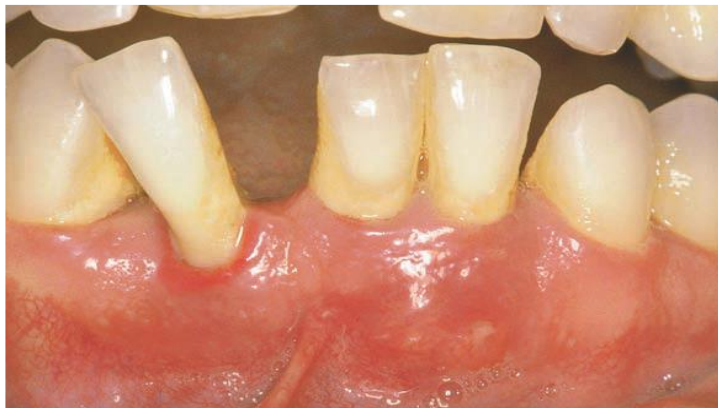- Physiological and pathological mobility
- Normal tooth mobility is less than 1mm
- Pathological tooth mobility when became severe in buccolingual and mesio-distal with vertical displacement



Trauma from occlusion

due to:

- excessive tooth mobility
- Widening of periodontal space
- Vertical or angular bone loss (intra-bony pocket)
- Pathological migration of teeth due to:
 - Tongue thrust
 - Abnormal forces
- Pathological migration of anterior teeth in young adult, which be s sign of localised aggressive periodontitis



Sensitivity or tenderness to percussion

- Acute inflammation of PDL
- Percussion at different angles of the long axis of the tooth

Gingiva



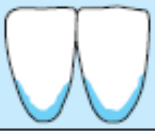
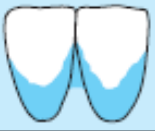
- Colour, size, contour, consistency, surface texture, position, bleeding on probing and pain

Types of gingival inflammation:

- Oedematous: smooth, glossy, soft and red colour
- Fibrotic: opaque, thick and rounded margin

Clinical indices in periodontal practice

Plaque index

Grade 0	No Plaque	
1	Thin plaque layer at the gingival margin, only detectable by scraping with a probe	
2	Moderate layer of plaque along the gingival margin; interdental spaces free, but plaque is visible to the naked eye	
3	Abundant plaque along the gingival margin; interdental spaces filled with plaque	

Abbreviation

PI

Grade

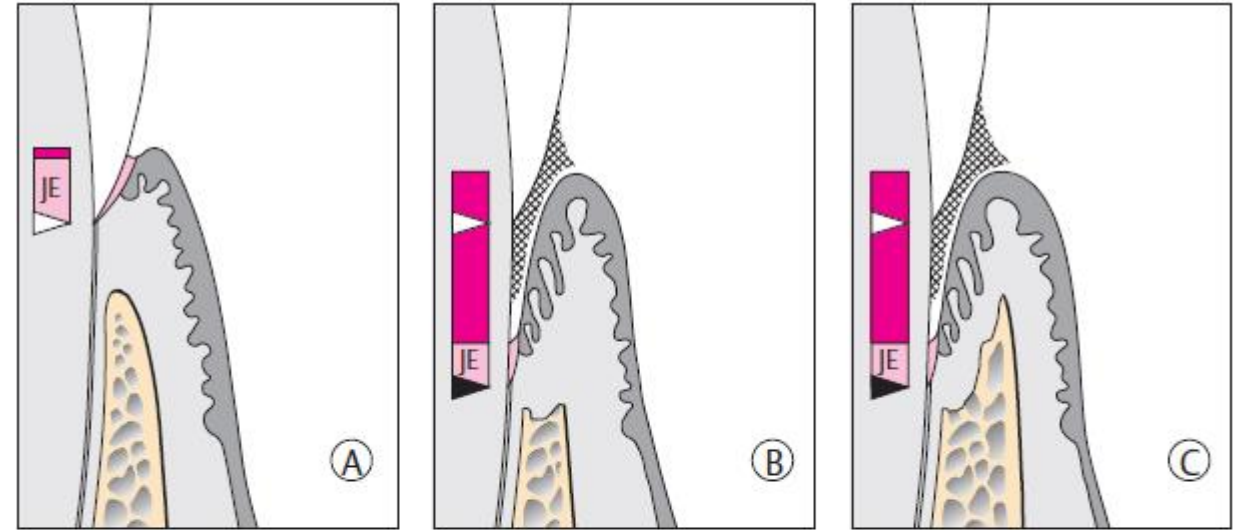
0–3

Gingival index

Grade 0	Normal gingiva; no inflammation; no discoloration (erythema); no bleeding
1	Mild inflammation; slight erythema; minimal superficial alterations. No bleeding
2	Moderate inflammation; erythema; bleeding on probing
3	Severe inflammation; severe erythema and swelling; tendency to spontaneous bleeding; possible ulceration.

Periodontal pocket

- Pocket depth
- Attachment loss level
- Type of pockets whether supra or intrabony



References

- Clinical Periodontology and Implant Dentistry By Jan Lindhe
- Colour Atlas of Dental Medicine and Periodontology

Control of microbial growth

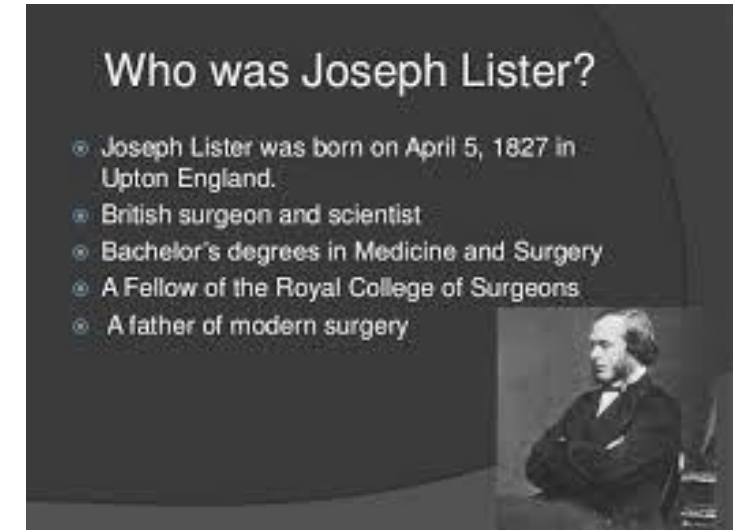
Introduction

- Microorganisms are agents of contamination, infection and decay
- Therefore; it is necessary to remove them from materials and the operating areas
- In early civilisation, people practised salting, pickling, smoking and exposure to sunlight
- In the mid of 1800 a British surgeon developed an aseptic technique to prevent contamination of surgical wounds after nosocomial infections (a disease originating in a hospital) caused death in 10% of surgeries.
- In addition, 25% of mothers delivering in hospitals died due to infection

Sterilisation

The process of destruction or removal of all microorganisms including their spores
It should

- Completely remove all kinds of microbes (bacteria, mycobacteria, viruses and fungi) by physical or chemical methods
- Be effective to kill bacterial spores



Sterilant: material or method that usually used to remove or kill all microbes

Cleaning: a process which removes visible contamination but does not mean to destroy all microorganisms. This cleaning is necessary to effective disinfection or sterilisation

Asepsis: A term used to describe methods, which prevent contamination of wounds and other sites by ensuring that only sterile object and fluids come into contact with them

Antisepsis: a procedure or application of an antiseptic solution or an agent which inhibit the growth of microorganisms, while remaining in contact with them

Disinfection: a process that **reduces** the number of viable microorganisms to an acceptable level, however; it may not be able to inactivate some viruses and bacterial spores

Sanitization: a process that reduces microbial population on an object to a safe level

Decontamination: a process that removes the pathogenic microorganisms from an object to make it safe to handle

To achieve a proper sterilisation of any instrument:

- Pre-sterilisation cleaning
- Sterilisation process
- Aseptic storage

Pre-sterilisation cleaning

- Removal of the organic materials, blood and saliva, which provide protective barrier for microorganisms and prevent its destruction
- This can be achieved by: **manual**, **ultrasonic** and **mechanical washing**

Manual cleaning

- Simplest and cheapest method but it is time consuming and difficult to achieve
- Heavy duty gloves and glasses must be worn to protect from needle prick and to protect eyes
- Soaps and detergents are usually used

Ultrasonic cleaning

- It is conversion of electrical energy into vibratory sound waves, which pass through a soap solution containing the instruments
- Used mainly for burs, bone files, bone cutter, artery forceps and saw... etc

Mechanical washing

- High pressure jets of water with or without a detergent which remove debris from the small instruments such as burs

Methods of control

- Physical and chemical
- Physical includes heat, irradiation, filtration and mechanical removal
- Chemical control involves the use of antimicrobial chemicals

Factors influence the effectiveness of antimicrobial treatment

1- Number of microbes: the more the microbes present the more time it takes to eliminate population

2- Types of microbes: endospores are very difficult to be destroyed. Vegetative pathogens vary in susceptibility to different methods of microbial control

3- Environmental influences: presence of organic material such as blood, saliva etc. tend to inhibit antimicrobials

4- Time of exposure: is more effective at longer time. In heat treatment, the longer exposure compensates for lower temperature.

Factors affecting efficacy

Nature of site: stability, porosity and chemical nature

Microorganism: degree of resistance, spores, viral envelope, protozoan cysts

Environmental conditions: acidity (pH), temperature, presence of organic material

Physical methods of microbial control

Heat

- Kills microorganisms by degenerating their enzymes and other proteins.
- Heat resistance varies widely among microbes
- Fast, reliable and inexpensive
- Does not produce potential toxic substances

Types of heat control:

- Moist heat
- Dry heat
- Pasteurization

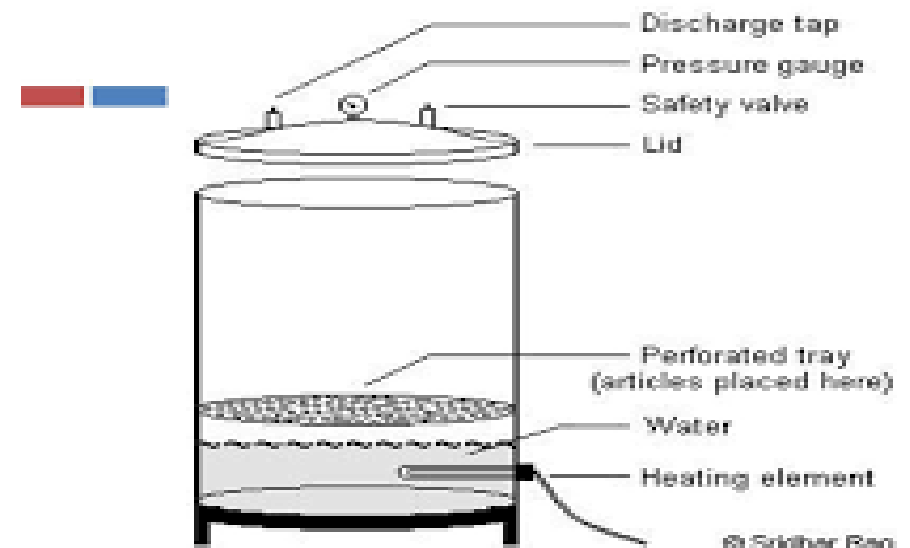
Moist heat: kills microorganisms by coagulating their proteins

Boiling: heat to 100°C or more will kill vegetative forms of bacterial pathogens.

- Most pathogens can be killed within 10 minutes or less
- Endospores and viruses cannot be killed that quickly
- In general: moist heat is much more effective than dry heat

Autoclave: is a chamber which filled with hot steam under pressure. It is a preferred method of a sterilisation, unless a material is going to be damaged by heat, moisture or high pressure.

- The steam temperature reaches 121°C at a twice atmospheric pressure
- All organisms and endospores are killed within 15 minutes



Dry heat

- Direct flaming: used to sterilise inoculating loops and needles. They should be heated until it has a red glow
- **Incineration**: effective way to sterilise disposable items (paper cups, dressing) and biological waste
- **Hot air sterilisation**: place in the oven, which required 2 hours at 160-170°C for sterilisation
- However; moist heat is more effective than dry heat
- Killing is due to dehydration, oxidation of microorganisms and protein denaturation

Irradiation

Used for sterilisation, by killing or inactivate microorganisms, it is two types

1- **Ionizing radiation** such as X-rays, gamma rays and high speed electrons

2- **Non-ionising radiation** such as ultraviolet light and infrared light

1-Ionising radiation

- X-rays, gamma rays and cosmic rays are highly lethal to DNA and other vital constituents
- They have high penetration power
- There is no considerable increase in temperature
- Therefore; it is referred to as cold sterilisation
- Commercial factories use gamma radiation for sterilising plastics, syringes, swabs and catheters

Non-ionising radiation

There are two types

A- Ultraviolet (UV): is considered as germicidal at a wavelength of 2537 Angstroms. UV destroy microorganism's DNA

Used mainly for air and water purification in the hospitals

B- Infrared: is most commonly used to purify air, such as in the operating room. It is effective, although has no penetrating ability

Chemical methods

- There is no available chemical solution to sterilise instruments through immersed them in it
- There is a risk of producing tissue damage if some residual solution is carried over into the wound, while it is being used

Mechanism of action of chemical disinfectants

- 1- Cell membrane injury
- 2- Coagulation and denaturation
- 3- Interactions with functional groups of proteins

1- Aldehyde compounds

A. Formaldehyde: a broad-spectrum antimicrobial agent, used for disinfection, has limited sporicidal activity. It is hazardous substance, inflammable and irritant to the eye, skin and respiratory tract

B. Glutaraldehyde: It is solution of 2% glutaraldehyde, required immersion of 20 mins for disinfection and 6-10 hours of immersion for sterilisation

- It is a high level disinfectant

2- Alcohols

- Act as denaturing bacterial proteins
- Solutions of 70% ethanol which are more effective than higher concentrations. The presence of water can speed up the process of protein denaturation

3- Iodophor compounds

- Many studies have shown that iodophor compounds are the most effective antiseptics.
- These compounds are effective against most bacteria, spores, viruses and fungi
- Most commonly used as surface disinfectants along with hypochlorite

4- Biguanide

The most commonly used biguanide compound is **chlorhexidine**

- Powerful non- irritating antiseptic that disrupts bacterial cell membrane
- It persists on skin for long period of time and that is why it is extensively used for surgical scrubbing, neonatal bath, mouth wash and general skin anti-septic

5- Hydrogen peroxide

- Oxidizing properties allow it to destroy wide range of pathogens
- Biggest advantage is short cycle time
- Used in 35% to 90% concentration

References

- Clinical Periodontology and Implant Dentistry By Jan Lindhe
- Colour Atlas of Dental Medicine and Periodontology

Advances in periodontal management

Periodontitis is a dynamic disease process characterised by periods of disease progression, remission and exacerbation

Diagnosis of periodontal disease includes different levels

- 1- Diagnosis of periodontal health versus disease
- 2- Classify the different types and severity of gingivitis and periodontitis
- 3- Decide whether the patient periodontitis is **active** or **arrested** or **in remission**

In conventional diagnosis and classification of periodontal disease, it depends on clinical assessment with many factors as:

- 1- presence or absence of clinically detectable inflammation
- 2- Extent and pattern of clinical attachment loss
- 3- Rate of progression
- 4- Patient age and onset
- 5- Presence or absence of miscellaneous signs and symptoms including pain, ulceration and amount of observable plaque and calculus

In most cases, the conventional diagnostic procedures are sufficient to design an effective treatment plan

- However, these methods have poor sensitivity in diagnosis patients with active sites of disease progression

Therefore, currently the scientists introduce other factors in the progress of diagnosis as risk factors which may predispose individuals to disease initiation and progression

The hope is to find a better way in diagnosis of periodontal disease through

- Differentiation between periodontal disease
- Identifying people and teeth that are susceptible to disease initiation and progression
- Monitor the response to treatment

Advances in clinical diagnostic methods

1- **Gingival bleeding** is an indicator of inflammatory lesion but its relation to disease activity is not clear yet

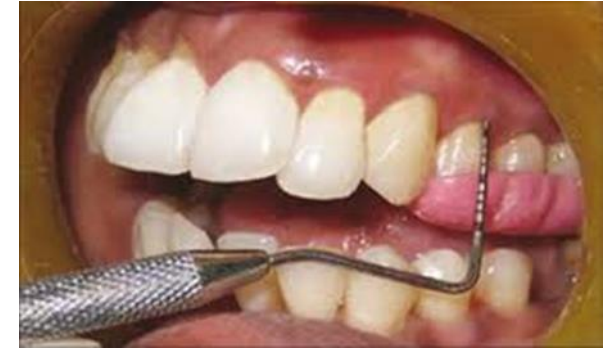- The normal force applied on probing is 0.25 N
- The presence of positive bleeding on probing is not an indicator, however; negative or absence of bleeding indicate health condition

2- Probing technique, controlled force, standardized probes

The periodontal probe is the most widely used diagnostic tool for clinically assessing connective tissue destruction as consequences to periodontitis

Problems associated with conventional probe are:

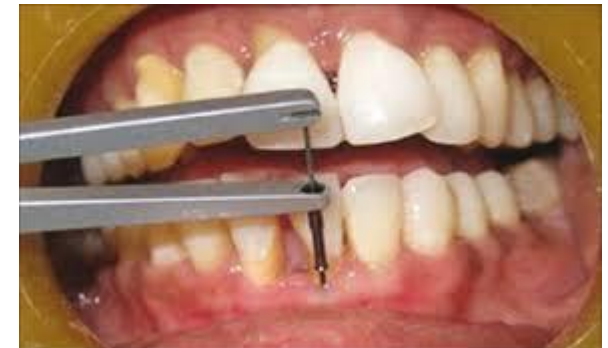- 1- Probing technique
- 2- Force
- 3- Probe diameter and angulations
- 4- Presence of inflammation



Several automated probes have been recently developed to overcome some of error source

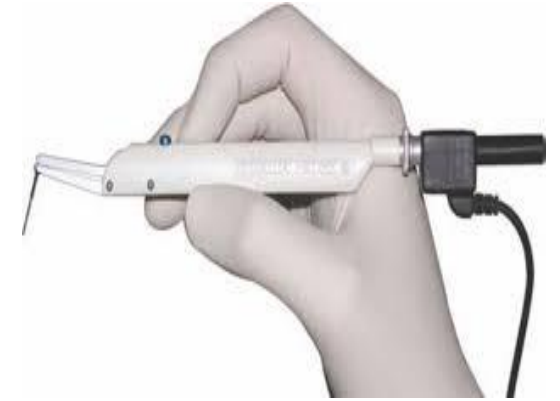1- **Automated Florida disc periodontal probe** gives a certainty of 99% detection of the less than 1mm loss of attachment level

- It utilises a reproducible occlusal landmark or a customised stent margin as a reference land mark
- The probe hand piece connected to a monitor for digital read out and foot switch all to computer
- It applied a constant force through a coil spring inside the probe
- **Advantage:** applied a constant force and no need for assistance
- **Disadvantage:** lack of tactile sensation, under estimation of deep probing points and fixed probing force



2- Automated Foster-Miller probe: it registers the CEJ as its attachment level landmark

- Some investigations reveal that this probe detect up to 0.2mm loss in attachment
- The disadvantage of such probe is time consuming



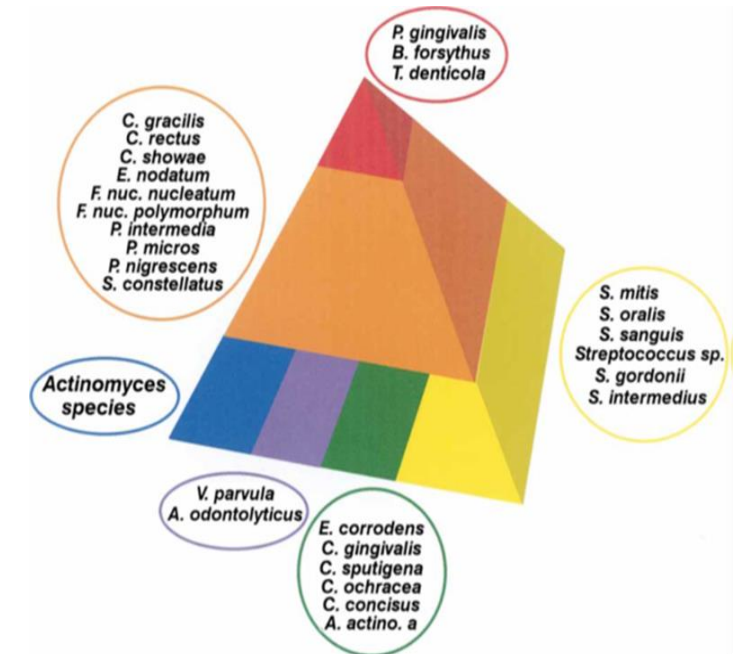
3- Pressure sensitive probe: it has a standardised, controlled insertion pressure

- 30 gm → tip with the junctional epithelium
- 50 gm → periodontal osseous defect

It uses a fabricated stent for reproducibility

Advances in microbiologic analysis

- Although more than 300 bacterial species make up the oral flora, it is currently thought that only a few either alone or in combination initiate the progression of periodontitis
- Evidence related to *Actinomyces*, *actinomycetemcomitans* (AA), *porphyromonas gingivalis* (Pg), *Bacteroides forsythus* (Bf)
- In addition, there is other microorganisms which are thought to have etiologic role such as: *Comphylobacter rectus*, *Euobacterium nodatum*, *Fusobacterium nucleatum* and *Prevotella intermedia*



Uses of Microbiologic analysis

- 1- Support the diagnosis
- 2- Aid in treatment planning
- 3- Good indicator of disease activity

Culture techniques have been the primary method of identifying putative pathogens, It allows:

- Characterising subgingival flora in terms of count , motility and morphology
- For specification and antibiotic susceptibility testing

In case of plaque; it can be done under anaerobic condition using selective and non selective media

Limitation of cultures:

- 1- Technical problems
- 2- Cultivating micro-organisms can be both time consuming and costly
- 3- Low sensitivity, organisms lesser than 10^3 is difficult to be detected

Molecular biology techniques

The principal base is to analyse DNA and RNA and protein structure. This relies on species specific genomic for microbial identification

1- DNA- analysis method: includes DNA probe and oligonucleotide probe

Analysis steps:

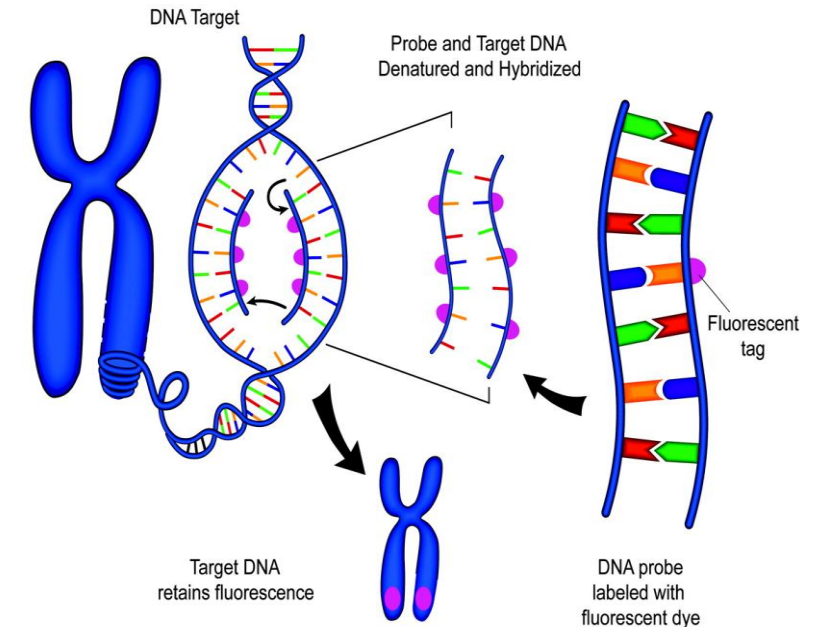
First: a labelled DNA (probe)s are constructed with a radioactive or enzyme detection system

Second subgingival plaque are collected on a sterile paper points or dental currettes and enzymatic ally single, stranded, denaturized DNA fragments

Third the unknown fragments are then exposed to complementary labelled probe and allow to hybridization

Test response reflects both the presence and approximate number of tented pathogen up to 10³

- Most often the DNA probe can test *p. gingivalis*, *prevotella intermedia*, *A.A. ,Eikenella corrodens*, etc.



2- Checkerboard DNA-DNA hybridisation technology is recently established technique that gives a simultaneous and quantitative analysis of up to 28 plaque samples against 40 microbial species (Socransky 1994)

- DNA checkerboard method offers the ability to include more potential periodontal pathogens in large scale studies with a single analysis than in usually practicable with cultural analysis
- By this method the associated pathogens related to periodontitis are set in clusters known as plaque complex each colour represents a cluster of associated periodontal pathogens

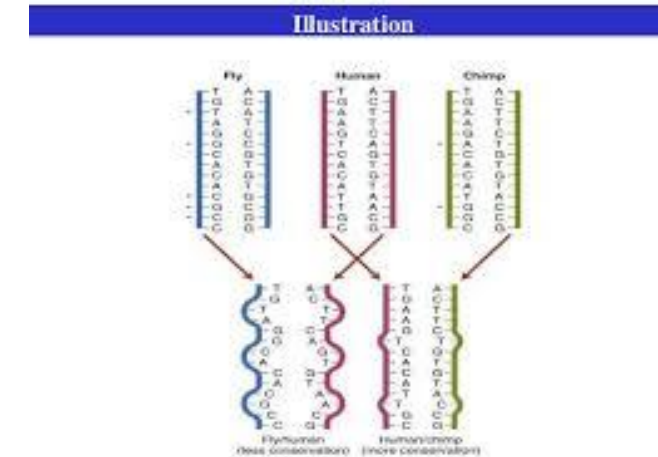
3- Polymerase chain reaction (PCR) this reaction is an in-vitro enzymatic reaction that involves the application of specific DNA sequences

- The bases of PCR is the use DNA polymerase which is an enzyme that catalyses the formation and repair of DNA and can make a copy of the entire DNA in each chromosome

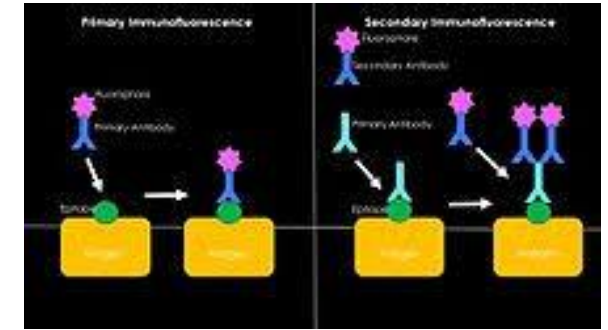
Immunologic-based tests for putative pathogens

Detecting subgingival pathogens using monoclonal antibodies specific antigens

- One technique for this immunofluorescent microscope
- The immunofluorescent assay can be done in two ways: direct and indirect



- **Direct method** include the interaction between antibody that conjugated with fluorescent marker of bacterial cells to make immune complex
- **Indirect method** include the interaction between immune complex (primary antibody + bacterial cells) with secondary fluorescent conjugated antibody



Enzyme linked immunofluorescent assay (ELISA) an enzymatic ally derived colour reaction, which can detect serum periodontal pathogens

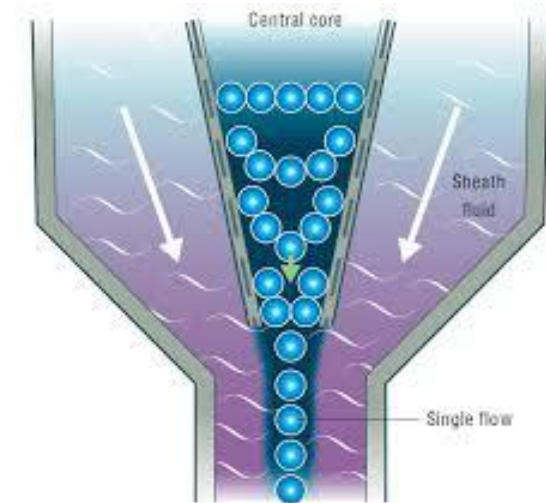
Flow cytometry

A technique for identifying and sorting cells and their components as DNA by staining with fluorescent dye and detecting the fluorescence usually by laser beam illumination

Advances in characterising host response

Assessment of host response by studying mediators as a response to bacteria or local release of inflammatory mediators or enzymes as in response to infection

- The samples come from saliva, serum and gingival crevicular fluid (GCF)



Identification of host constituent in GCF

GCF is a serum like exudates which baths the gingival sulcus or periodontal pocket and follows an osmotic gradient with local tissue

- As this fluid traverse from the host microcirculation, through inflamed tissue and periodontal pocket, it captures mediators involved in the destructive host response and by products of local tissue metabolism

GCF can be collected by:

- Filter paper or strips
- Capillary tube include micropapillary tube, micropipette and microsyringe
- Intrасulcus washing

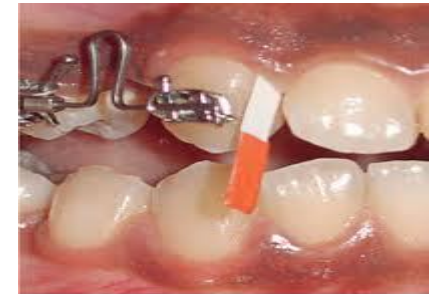
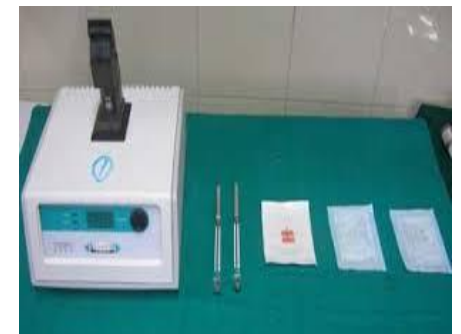
FIGURE 3 – Absorbent paper strip used for collection of gingival fluid.

The constituents of GCF can be quantified or qualified with a specific assay such as ELISA or periotron

Some of diagnostic markers in GCF are

- Arachidonic acid metabolites
- Cytokines such as interleukins (IL-1B, IL-8)
- Cathepsin like activities or mediators
- Proteases and collagenase and alkaline phosphatase enzymes



Saliva markers

Saliva is a transudation from serum, secreted from oral salivary glands

- It provides an easy method for collection which is either stimulated or unstimulated method

Saliva may contain locally and systemically derived markers of periodontal disease such as:

- Proteins and enzymes
- Hormones
- Bacteria and their products
- Ions
- Micro and macro elements
- Host cells

Advances in radiographic assessment

Conventional radiograph is a traditional method to assess the alveolar bone destruction. It is very specific but lacks sensitivity

Shortcomings associated with conventional radiograph

- Variations in the projection geometry
- Variations in contrast and density due to differences in film processing, voltage and exposure time
- Masking of osseous changes by other anatomic structures

Digital radiograph (DR) it enables the use of computerised image which can be stored and manipulated

Advantages: digital storage, image enhancement and radiation dose reduction

Two D.R. systems

Direct method: used charged coupled device, sensor linked with fiber optic to computer system

- It provides $1/3 - 1/2$ reduction dose

Indirect method: used phosphor luminescence plate which is flexible, film like radiation energy sensor placed intraorally and exposed to conventional X-ray tube, a laser scanner read the exposed plate and produce digital image

Subtraction radiography

Conversion of serial radiographs into digital images. The image then superimposed and the resultant composite viewed on a video screen

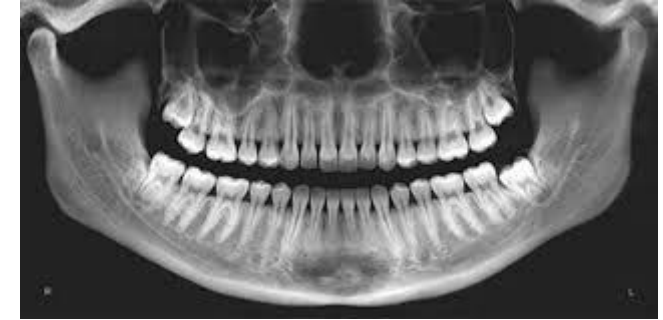Bone gain  lighter area

Bone loss  darker area

Limitation of this technique is the need to paralleling technique and accurate superimposition

Advantages

- Correlation between change in alveolar bone shown in subtraction radiograph and CAL change, post therapy
- Increased detect ability of small osseous lesions
- Both quantitative and qualitative visualization
- More sensitive



Disadvantages

Identical projection alignment during sequential radiographs

Computer-assisted densitometric-image analysis (CADIA)

3D quantification of bone volume change. The device includes camera, image processor and computer

- A video camera measures the light transmitted through a radiograph and the signals from camera are converted into gray-scale image

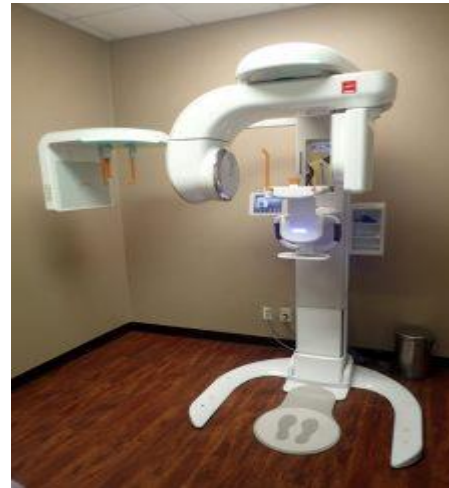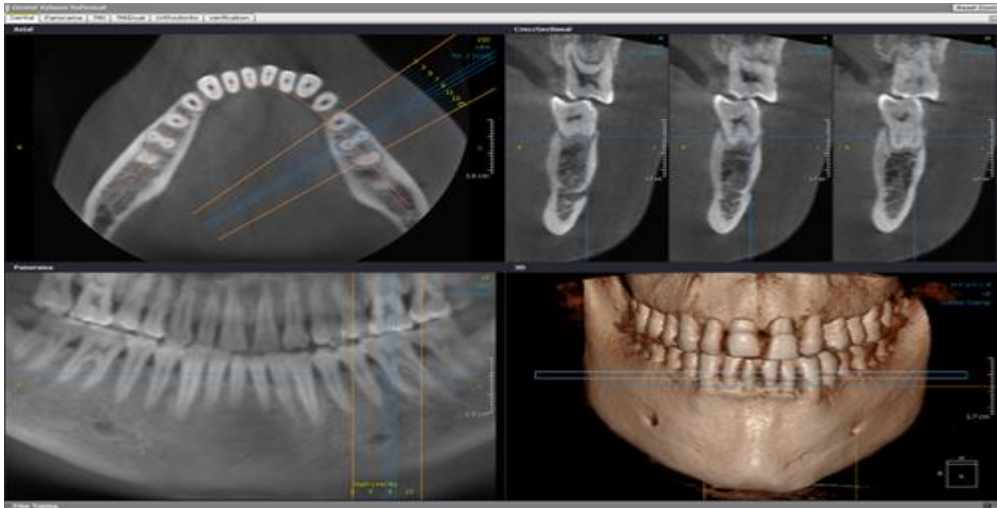
Advantages

- This method increases accuracy reproducibility and sensitivity
- Measure quantitative change in bone density overtime

Cone beam computed tomography (CBCT)

Utilised a cone shaped source of radiation and an area detector and that acquires a full volume of images in a single rotation with no need for patient movement

- CBCT system accompanying software any number of diagnostic images can be generated



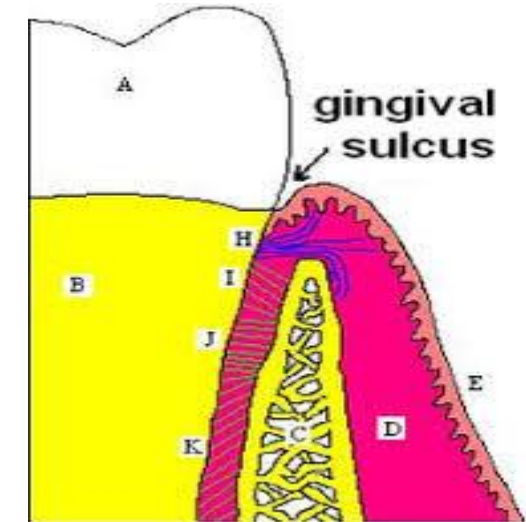
References

- Clinical Periodontology and Implant Dentistry By Jan Lindhe
- Colour Atlas of Dental Medicine and Periodontology

Gingival and periodontal pocket

Tooth gingival interface

- The interface between the tooth and surrounding gingival tissue is a dynamic structure
- The crevice around the tooth is known as sulcus
- It is a constant state of flux due to microbial invasion and subsequent immune response
- There is 1mm of **junctional epithelium** and another 1mm of **gingival fibre attachment** comprising the **biological width**



Gingival sulcus

- A healthy sulcular depth is 3 mm or less
- Microbes accumulation lead to form biofilm
- These microbes if remain undisturbed, may pose a danger to the periodontal ligament (PDL)
- And they penetrate and destroy the delicate soft tissue and PDL
- This leads to deepening of the sulcus, recession, destruction of periodontium, accompanied by bone loss, teeth mobility and teeth loss

Periodontal pocket

- Is an inflammatory changes and **apical migration of junctional epithelium**
- It is also defined as a pathological deepening of the gingival sulcus, which occur by coronal movement of gingival margin and apical displacement of gingival attachment or both

Classification

1- According to the involved tooth surface

- a. Simple pocket:** involves one surface
- b. Compound pocket:** involves more than one surface
- c. Complex or spiral pocket:** originating on one surface and twisting around the tooth to involve one or more additional surfaces

2. According to its location

- a. Gingival pocket:** which is formed by gingival enlargement without destruction of underlying periodontal tissue. The sulcus is deepened because of increased bulk of the gingiva
- b. Periodontal pocket:** associated with destruction of underlying supportive tissues

Gingival pocket

This pocket presents when the marginal gingiva experience an oedematous reaction, whether due to localised irritation and subsequent inflammation, systemic issues or drug induced gingival hyperplasia

- This phenomenon is referred to a false pocket (pseudopocket)
- The epithelial attachment does not migrate
- The only anatomical landmark experiencing migration is the gingival margin in a coronal direction
- A gingivectomy is necessary to reduce the gingival pocket to a healthy 1-3mm condition

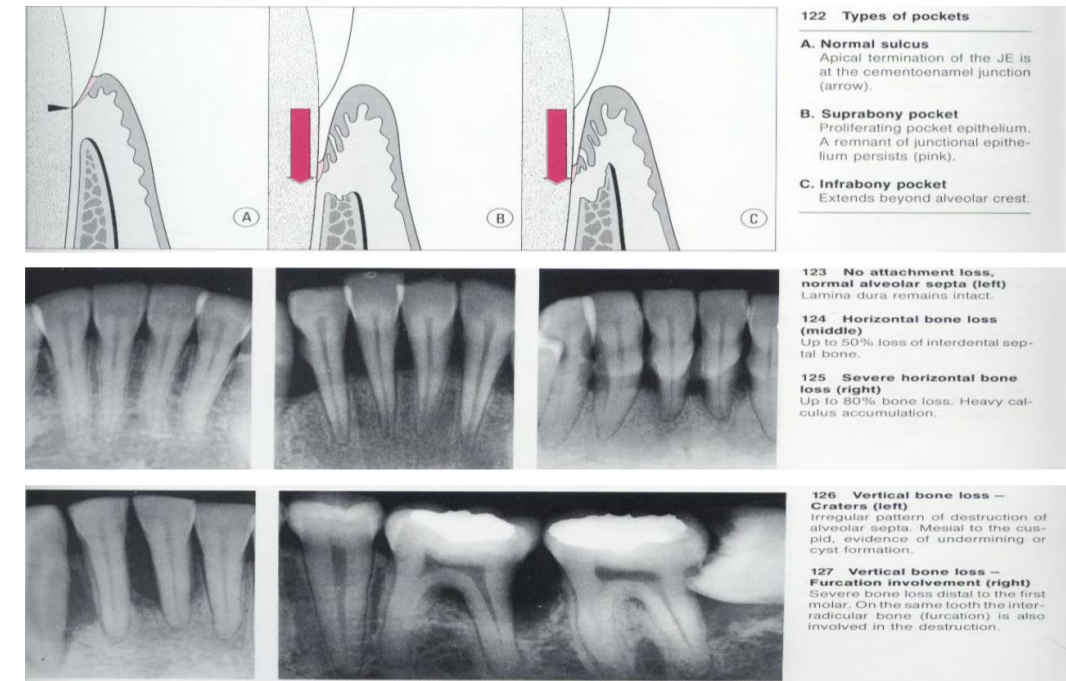
3. According to its relation to alveolar crest

a. **Suprabony pocket:** also called supra crestal or supra alveolar

- The base of the pocket is coronal to the level of underlying bone. The bone loss is **horizontal**

B. **Infrabony pocket:** also known as sub crestal or intra alveolar pocket

- The base of the pocket is apical to the level of adjacent bone. The bone loss is **vertical**



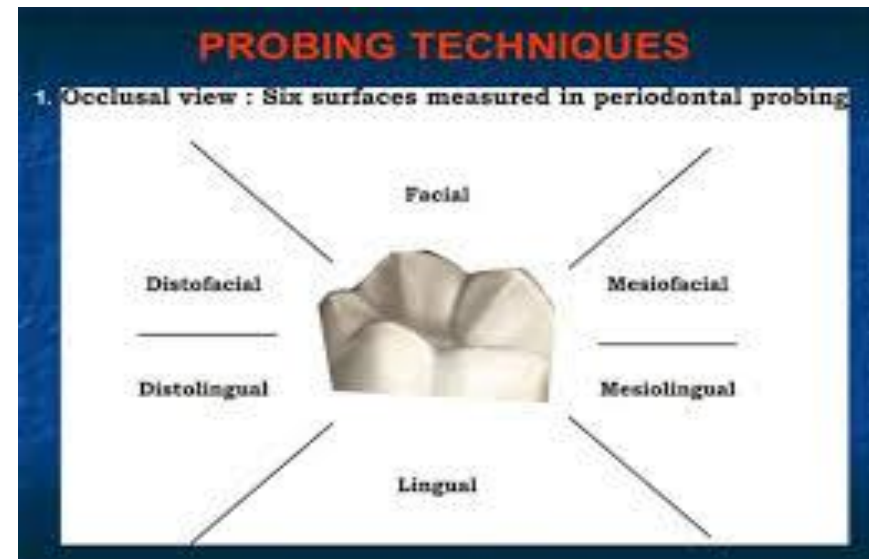
Diagnosis & detection of pockets

- 1- Careful exploration with periodontal probe
- 2- Radiographic: pockets are not detected by the radiographic examination because pockets are soft tissue changes

Probing techniques can reveal the extent of the disease

-Six surfaces can be measured in periodontal probing

- 1- Facial
- 2- Lingual
- 3- Distofacial
- 4- Distolingual
- 5- Mesiofacial
- 6- Mesiolingual



- **In multirooted teeth** , the possibility of furcation involvement would be carefully explored with specially designed probe (eg Nabers probe)
- The probe should be inserted parallel to the vertical axis of the tooth and walked circumferentially around each tooth to detect the area of deepest penetration
- **To detect internal crater:** the probe should be placed obliquely from both facial and lingual surfaces to explore the deepest point of the pocket which is located beneath the contact point

The typical probe is tapered, rod-like instrument, calibrated in millimetres with a blunt rounded tip

Types of calibrated periodontal probe

Marquis color-coded probe: its calibrations are in 3mm sections, markings are 3,6,9,12mm

MARQUIS COLOR CODED PROBE



- Calibrations are in 3mm sections.
- Markings are 3,6,9,12mm.

University of Michigan 'O' probe with William markings

- Markings are 1,2,3,5,7, 8,9,...



The UNC-15 probe: 15 long and markings are at each mm and coding at the 5th, 10th and 15th mm
Millimetre markings at 1,2,3,4,5,6,7,8,9,10,11,12,13,14 and 15 mm



World health organization (WHO) probe: prescribed in 1978: the probe was designed for two purposes:

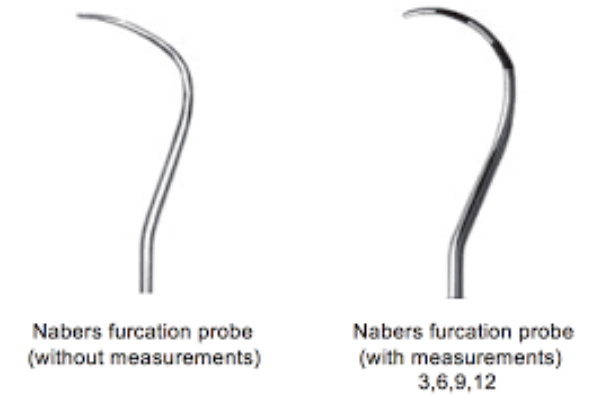
- Measurement of pocket depth
- Detection of subgingival calculus

It is using in the assessment of CPITN (Community periodontal index for treatment needs)



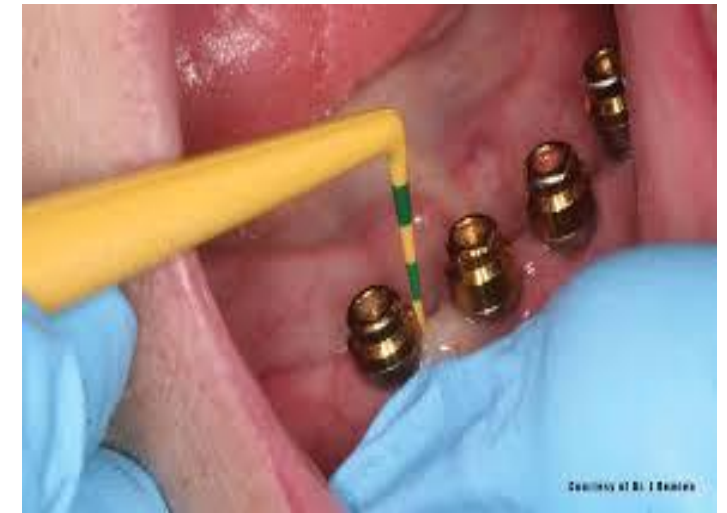Naber's furcation probe: it is used to determine the extent of furcation involvement on a multirooted teeth

- It has a curved working end for accessing the furcation area
- It has a blunt end
- The depth of the insertion of the probe into the furcation area determines the degree of furcation involvement



Peri-implant probe: can measure the level of mucosal margin relative to a fixed position on the implant

- The probing depth is often measure of the thickness of surrounding connective tissue and correlates most consistently with the level of surrounding bone
- The presumed healthy condition around an implant is **3 mm** in all surfaces
- The results obtained by periimplant probing cannot be interpreted as same as the natural teeth because of differences in the surrounding tissues that support implanted teeth
- Around natural teeth, the periodontal probe is resisted by the insertion of supra-crestal connective tissue fibres into the cementum of root surfaces, where are not equivalent fibres around implants

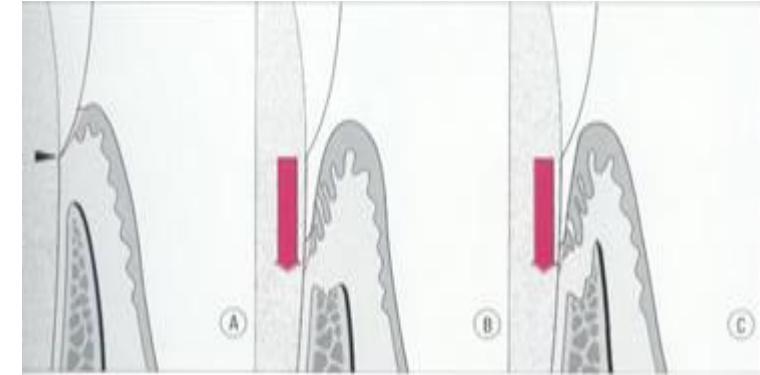


References

- Clinical Periodontology and Implant Dentistry By Jan Lindhe
- Colour Atlas of Dental Medicine and Periodontology

Pathogenesis of periodontal disease

- Accumulation of microorganisms on the supragingival tooth surface and its extension into gingival sulcus
- Inflammatory changes in the connective tissue wall of the gingival sulcus
- Cellular and fluid inflammatory exudate causes degeneration of the connective tissue including the gingival fibres
- Collagen fibres gets destroyed apical to the junctional epithelium and the area becomes occupied by the inflammatory cells and edema
- The coronal portion of the junctional epithelium detaches from the root as the apical portion migrates
- Polymorphonuclear neutrophils invade the coronal end of the junctional epithelium become increased in number
- With continued inflammation the gingiva increase in bulk and the crest of the gingival margin extends coronally
- The junctional epithelium continues to migrate along the root and separate from the root



Mechanisms of the collagen loss

There are two mechanisms involved

- **First mechanism:** collagenases and other enzymes secreted by fibroblast, PMNs and macrophages. These enzymes degrade the collagen and other matrix macromolecules into small peptides which are called as matrix metalloproteinase

- **Second mechanism**

Fibroblast phagocytizes collagen fibres by extending cytoplasmic processes to the ligament-cementum interface and degrade the inserted collagen fibrils and the fibrils of cementum matrix

Histopathology

A. Epithelial changes

- Epithelium becomes degenerated and atrophied
- Inner aspect of the pocket wall becomes ulcerated
- Pus occurs in the pocket with suppurative inflammation of the inner wall

B. Connective tissue changes

- The connective tissue is edematous and densely infiltrated with plasma cells, lymphocytes and PMNs
- Blood vessels increased in number, dilated and engorged in subepithelial connective tissue layer
- Single or multiple necrotic foci are presented in the connective tissue
- Proliferation of endothelial cells, with newly formed capillaries, fibroblasts and collagen fibres

C. Root surface wall of the pocket

- Root surface forms the medial wall of the pocket
- The root surface that get exposed to the oral environment as a result of periodontal attachment loss undergo **Structural, chemical and cytological changes**

Structural changes

- Exposure of cementum to the oral environment
- Minerals (Ca, F,...) present in saliva tend to get deposited on the cementum surface
- An area of hypermineralisation
- Root surface is exposed to oral fluids and bacterial plaque
- Proteolysis of embedded remnants of Sharpey's fibres
- Area of demineralisation
- Root caries yellowish or brown patch

- Soft and lethargy on probing
- Patient feels hypersensitivity to thermal changes and sweets
- Pulp exposure may occur in sever forms

Chemical changes

- Cementum exposed to saliva may absorb calcium, phosphorus, magnesium and fluoride
- This increases in mineral content of the root surface alters the chemical composition of the cementum, making it resistant to dental caries

Cytotoxic changes

- Histologic studies of periodontally involved cementum have shown the presence of bacteria or endotoxins in the cementum

Pocket probing

There are different pocket depths

1) Biological or histologic probing depth: distance between gingival margin and the base of the pocket

2) Clinical or probing depth: distance to which a probe penetrates into the pocket

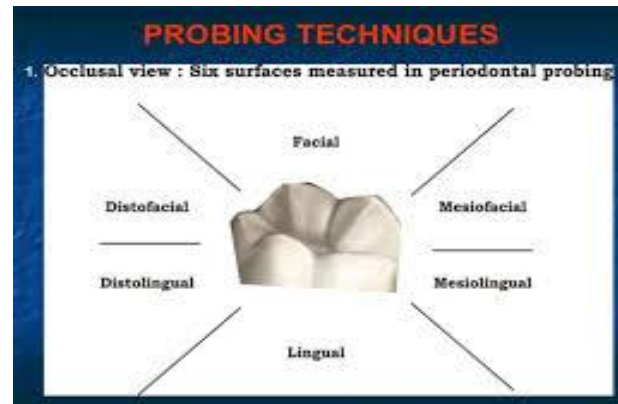
The standardized force used for penetration of probe is 25 pounds or 23 grams (0.75) N

Probing pocket depth PPD: distance between base of the pocket and gingival margin

The extent of disease refers to the proportion of the dentition affected by the disease in terms of percentage of sites

- Sites are defined as the positions at which probing measurements are taken around each tooth and generally six probing sites around each tooth are recorded as follows

- 1- Mesiobuccal
- 2- Mid-buccal
- 3- Distobuccal
- 4- mesiolingual
- 5- Mid-lingual
- 6- Distolingual



If up to 30% of sites in the mouth are affected, the manifestation is classified as localized for more than 30% the term generalised is used

Level of attachment loss (CAL): distance between base of pocket and a fixed point on the tooth such as CEJ

Severity

The severity of disease refers to the amount of periodontal ligament fibres that have been lost, termed clinical attachment loss

- According to the **American Academy of Periodontology** the classification of severity is as follows
- Mild: 1-2mm of attachment loss
- Moderate: 3-4mm of attachment loss
- Severe: \geq 5mm of attachment loss

Periodontal pocket as healing lesions

Periodontal pockets are inflammatory lesions and constantly undergoing repair

- Complete healing does not occur because of persistence of bacterial attack which continues to stimulate an inflammatory response causing degeneration of new tissues

Edematous pocket walls: when the inflammatory component predominates, the lateral wall appears soft, edematous, friable, with smooth shiny surface and bluish red discoloration

Fibrotic pocket wall: when reparative changes predominates, the gingiva appears fibrotic and pink

In some cases both lesions present in the same pocket as outer surface of a pocket wall is fibrotic , the inner surface of soft tissue wall is inflamed and ulcerated

Clinical features

- A.
 - 1- Bluish red discoloration of the gingival wall of the pocket, this happened due to circulatory stagnation
 - 2- Fragility of tissue: due to destruction of gingival fibres
 - 3- Smooth shiny surface due to atrophy of the epithelium and edema
 - 4- Pitting on pressure due to edema and degeneration
- B. Gingival wall may be pink or firm, when fibrotic changes predominates over exudation and regeneration
- C. Bleeding on probing due to
 - 1- Increasing vascularity
 - 2- Thinning and degeneration of epithelium
 - 3- Proximity of engorged vessels to inner surface

4- Probing is generally painful due to ulceration of the inner aspect of the pocket wall

5- Pus may be present due to suppurative inflammation

6- Other clinical features

- Thickened marginal gingiva
- Loss of stippling
- Tooth mobility and diastema formation

Signs and symptoms

1. Total loss of attachment: clinical attachment loss (CAL) is the sum of **gingival recession** and **probing depth**

In early stages, periodontitis has very few symptoms, and in many individuals the disease has progressed significantly before patients are seeking treatment

Symptoms may include

- **Redness or bleeding** of gingiva while **brushing** teeth, using dental floss or biting into hard food (e.g. apples) (through this may occur even in gingivitis, where there is no attachment loss)
- **Gingival swelling** that recurs
- **Spitting out blood** after **brushing** of teeth
- **Halitosis** or **bad breath** and a **persistent metallic taste** in the mouth
- **Gingival recession** resulting in apparent **lengthening of teeth** (this may also be caused by heavy-handed brushing or with a stiff toothbrush)
- **Loose teeth**, in the later stages (though this may occur for other reasons as well)

Patients should realise gingival inflammation and bone destruction are largely painless

- Hence, people may wrongly assume painless bleeding after teeth cleaning is insignificant, although this may be a symptom of progressing periodontitis in that patient

Periodontal disease activity

- 1- Period of quiescence or inactivity this period characterised by reduced inflammatory response and little or no loss of bone and connective tissues
 - A build up of dental plaque with G-ve followed by
- 2- Period of exacerbation (bone and connective tissue attachment loss and pocket)

This period may last for **days, weeks, months** and eventually followed by period of remissions and quiescence in which G+ve bacteria proliferate and more stable condition is established

- **Clinical features** shows spontaneous bleeding on probing and greater amount of gingival exudates
- **Histological features**, pocket appear thin and ulcerated, infiltrate composed of plasma cells and PMNs

Treatment

Non-surgical treatment

- 1) Oral hygiene **motivation** and **instruction**
- 2) Scaling and root planning
 - Using curettes for subgingival scaling, root planning and removal of the soft tissue lining pocket
 - Root planning stroke should be moderate to light
 - Pull stroke for final smoothing and planning of root surface
 - Continuous series of long overlapping shaving stroke should be achieved
 - To avoid over instrumentation, a delicate transition from short, powerful scaling stroke to longer, lighter root planning strokes must be made as soon as calculus and initial roughness have been eliminated

Surgical treatment

Surgical depth reduction through different surgical procedures

- 1- Gingival curettage
- 2- Gingivectomy
- 3- Periodontal flap procedures
- 4- Osseous surgery
- 5- Periodontal regeneration procedures

References

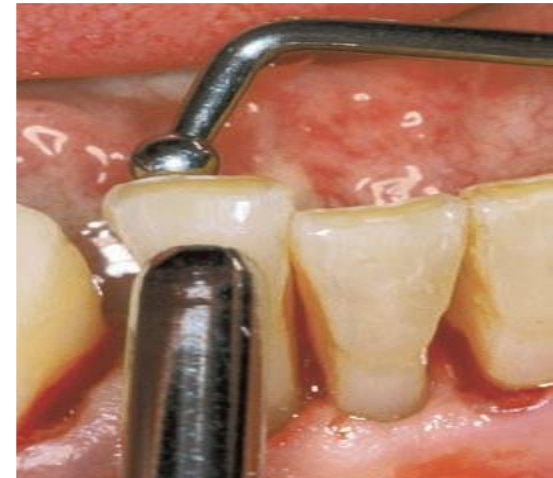- Clinical Periodontology and Implant Dentistry By Jan Lindhe
- Colour Atlas of Dental Medicine and Periodontology

Tooth mobility

Is loosening of a tooth in its socket & it is of two types physiologic and pathologic mobility

Physiologic mobility: refers to a large force exerted on the crown of a tooth surrounded by a healthy and intact periodontium, in which the tooth show tipping movement or it will tip within its alveolus until a closer contact has been established between root and marginal or apical bony tissue

- All teeth have a slight degree of physiologic mobility, which varies for different teeth and at different time of the day
- It is at the greatest on arising in the Morning and progressively decreased afterward
- This increased mobility is attributed to the extrusion of the tooth because of limited occlusal contact during sleep
- During the waking hours, mobility is reduced by chewing and swallowing forces which intrude the teeth in the sockets
- In addition, this mobility is less marked in persons with healthy periodontium than in those with occlusal habits such as bruxism and clenching



- Displacement of crown of the tooth can be increased by force application when the height of the alveolar bone is reduced but the remaining PDL have a normal width

Pathological mobility

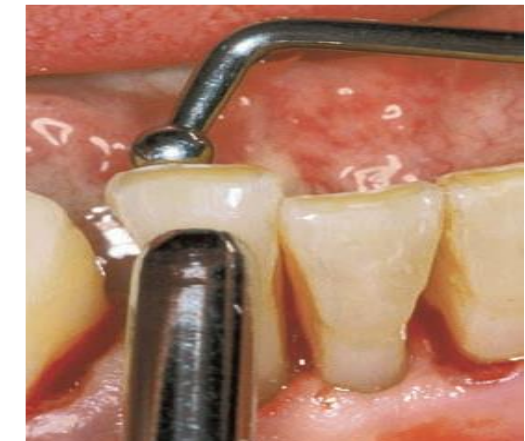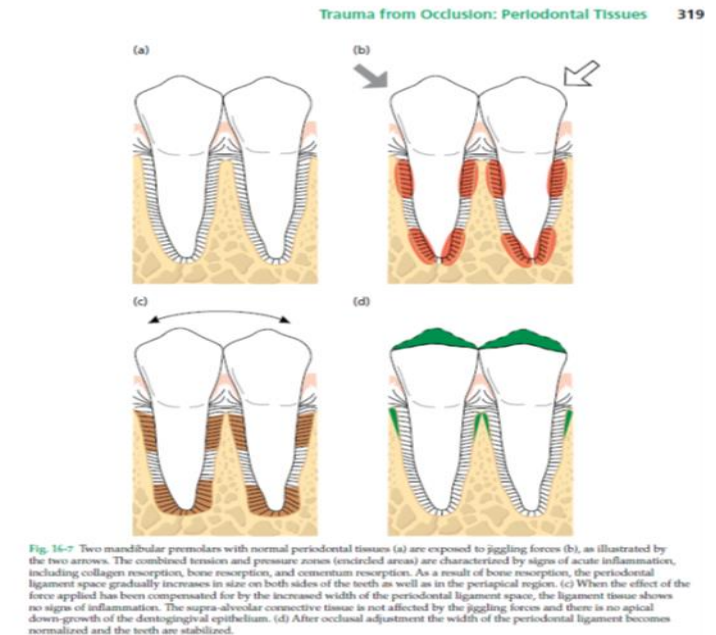
Is the progressive increasing tooth mobility, which may occur in conjunction with trauma from occlusion, is characterised by active bone resorption and indicates a presence of inflammatory alterations within the PDL

- Teeth mobility may be in horizontal or vertical direction

Horizontal tooth mobility

Is the ability to move the tooth in a facial-lingual direction in its socket.

- It is assessed by putting the handles of two dental instruments on either side of the tooth and applying moderate pressure in the facial-lingual direction against the tooth



Vertical tooth mobility

Is the ability to depress the tooth in its socket, and can be assessed using the end of an instrument handle to exert pressure against the occlusal or incisal tooth surface

Causes of tooth mobility

1- Advanced periodontal diseases and loss of supporting bone

Normally the crest of alveolar bone located about 1-2mm shorter than CEJ

- The amount of mobility depends on the severity of bone destruction and there will be a reduction in the height of bone

2- Gingival and periodontal inflammation

Mobility will occur by increase the infiltration of inflammatory excaudate fluid within the connective tissue

3- Trauma from occlusion

It is injury to the tissue produced by excessive occlusal forces or habits such as bruxism or clenching, which is a common cause for increased tooth mobility

- The pathological changes that occur because of trauma from occlusion are widening of periodontal ligament space and or destruction of the bone surrounding the root

4- Immediately following periodontal therapy

May cause transient mobility for a short period of time because of the surgical trauma (physical rather than bacterial) due to using of surgical instruments

- After 2-3 weeks, the mobility will disappear if the diagnosis, treatment plan and maintenance phase were done properly

5- Pulpal inflammation

Spread of inflammation from periapical area to the periodontal ligament may results in changes that increase tooth mobility

Factors that govern tooth mobility in a horizontal direction

- 1- The width of the periodontal ligament space (it is about 0.25mm determined by x-ray)
- 2- The height of alveolar bone (is 1mm apical to the CEJ)
- 3- Number of roots (multirooted teeth are less subjected to mobility than single rooted teeth)
- 4- The shape of the roots (short tapered shape root is more susceptible to mobility than normal size and wide roots)
- 5- The degree and duration of the applied force whether in normal or abnormal function

Classification of tooth mobility (TM)

TM is graded according to the following criteria:

Grade I: is the mobility of the crown 0.2-1mm in horizontal direction

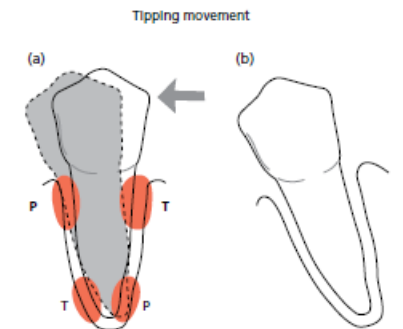
Grade II: mobility of the crown of the tooth exceeding 1mm in horizontal direction

Grade III: mobility of the crown of the tooth in vertical direction as well and the tooth becomes even depressed in its socket

Initial and secondary tooth mobility

A tooth which is surrounded by normal periodontium may be moved in horizontal and vertical directions may be forced to rotational movements

- clinically, tooth mobility is assessed by exposing the crown of the tooth to a certain force and determine the distance that the crown can be displaced buccal and or lingual direction
- The mechanism of TM was studied in details by Muhlemann (1954, 1960) who described a standard method for measuring even minor tooth displacement by means of periometer with a small force (100 pounds) is applied to the crown of a tooth
- The crown started to tip in the direction of the force and the crown is moved only 0.05-0.1mm
- This movement of the tooth is called initial tooth mobility (ITM), which is the result of intra alveolar displacement of the root
- In this movement there is pressure and tension zone
- In the pressure zone there is 10% reduction in the width of periodontal ligament and in the tension zone there is a corresponding increase
- In the ITM there is reorientation of the PDL fibres into a position of functional redness towards tensile strength and it differs from an individual to another and from tooth to tooth



- When large force (500 pounds) is applied to the crown, the fibre bundles on the tension side can not offer sufficient resistance to further root displacement
- The additional displacement of the crown is called **secondary tooth mobility (STM)**, which is allowed by distortion and compression of the periodontium in the pressure side
- The displacement of the crown with 500 pounds force applied may vary between teeth:

Incisors 0.1-0.12mm

Canines 0.05-0.09mm

Premolars 0.08-0.1mm

Molars 0.04-0.08mm

- This displacement found to be larger in children than adults and is larger in females than males (which increase more in pregnancy)

Signs and symptoms of TM

1- Patient awareness of mobility

Mobility is detected quite incidentally when patient's attention is brought to tooth by tenderness experienced on chewing

2- Functional discomfort

Pain may be expected following sudden tooth displacement when biting on hard food or with inadvertent trauma

3-Aesthetic

Anterior labial or lateral tooth displacement results in elongation of clinical crown with poor appearance

Treatment of increased tooth mobility

Situation I: increased mobility of a tooth with increased width of PDL but normal height of the alveolar bone

This case is seen in teeth with improper filling or crown restoration (high spot), which may lead to occlusal trauma

- This leads to increase the width of the PDL
- The PDL can physiologically adapt to this force without pocket formation
- In such case the bone resorption is a reversible process
- **The treatment can be carried out by elimination of occlusal interference**

Situation II: increased mobility of a tooth with increased width of PDL and reduced height of alveolar bone

- This case can be seen when teeth are properly treated for plaque associated periodontal disease, gingival health is established, however; periodontal structures are reduced
- Trauma from occlusion is seen when teeth are exposed to excessive horizontal forces and teeth become mobile
- Treatment in this case is **by occlusal adjacement and elimination of the excessive force or reduce it**
- Bone apposition will occur and the PDL will regain its width and the tooth will be stable

Situation III: increased mobility of a tooth with reduced height of alveolar bone and normal width of PDL

In teeth with normal width of PDL, no further bone apposition can occur

- If such an increased tooth mobility does not interfere with the patient chewing function or comfort, no treatment is required
- If the mobility disturb the patient so it can be treated by splinting and joining the mobile teeth with other teeth either by using composite fillings, fixed bridges

Situation IV: progressive increasing mobility of teeth as a result of gradually increasing width of PDL in teeth with reduced height of alveolar bone

This case can be seen in advanced periodontal disease, the tissue destruction may reach a level where extraction of one or several teeth can be avoided

- Teeth that remaining in such dentition are still available for periodontal treatment which may exhibit a progressively increasing mobility by force applied during function which disrupt the remaining PDL
- **Treatment is only by fixed splint to stabilize the hyper mobile teeth and to replace missing teeth**

Situation V: Increased bridge mobility despite splinting

In patient with advanced PD disease, the destruction of the periodontium has progressed to varying levels around different teeth and tooth surfaces in dentition

- Following proper treatment of the plaque-associated lesions, often including multiple extraction, the remaining teeth may display extreme reduction of the supporting tissues with increased tooth mobility and they may be distributed in the jaw in such a way that makes it difficult or impossible to obtain proper splinting effects even by means of cross-arch bridge and entire bridge/splint may exhibit mobility

An increased mobility of a cross-arch bridge/splint can be accepted providing that the mobility does not disturb chewing ability or discomfort and the mobility of the splint is not progressively increasing

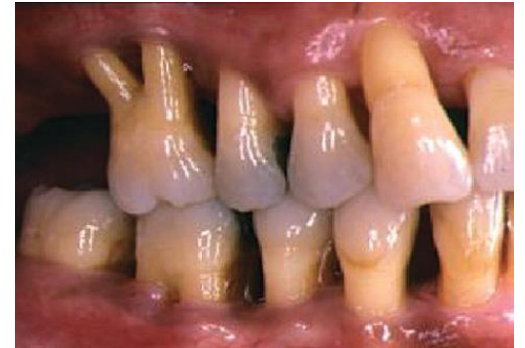References

- Clinical Periodontology and Implant Dentistry By Jan Lindhe
- Colour Atlas of Dental Medicine and Periodontology

Furcation involvement

This term refers to the invasion of the bifurcation and/or trifurcation of multirooted teeth by periodontal disease

- The primary aetiological factor is bacterial plaque which plays an important role in developing gingivitis and destructive periodontal disease



Consequently, therapeutic measures aimed to eliminate gingival inflammation and arresting progression of periodontal tissue breakdown must include the careful removal of microbial deposits from the tooth surfaces and establishment of home-care program which prevents recurrence of gross amount of plaque and calculus

- The progression of bacterial plaque apically along root surface may not occur only in vertical direction but also in horizontal leading to furcation involvement

Anatomical characteristics

The anatomy of the roots and the topography of the alveolar bone in the furcation areas of multi-rooted teeth in a periodontal patient can be examined if a mucoperiosteal flap is elevated

- General information regarding the anatomy of the furcation areas of multirooted tooth may be gained from ‘autopsy material’
- The position and spread of the roots of the maxillary molars often give rise to a large areas of interdicular supporting bone
- A thin buccal bone plates is sometimes associated with the presence of **fenestrations** and /or **dehiscence** in combination with a gingival recession
- The use of radiographs to identify the structures in the furcation area is of limited value
- In maxillary molars, usually only the buccal furca area can be properly identified, whereas the other furca areas become superimposed with bone structures
- Parallel and bite-wing film can be used to discover these areas

There are some morphological variations that must be considered in the diagnosis and treatment of furcation involved teeth:

1- Fusions between divergent roots

2- Cervical enamel projection or enamel pearl in the furcation areas, they occur approximately in 15% of molars

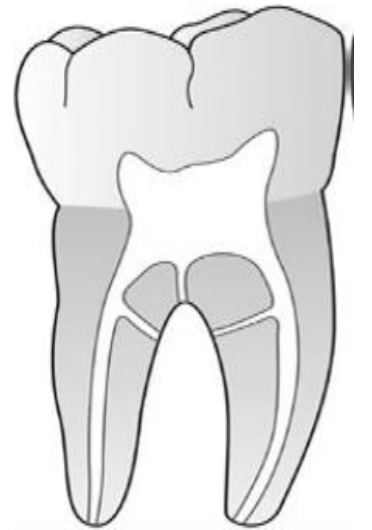
- They might cause plaque accumulation and must be removed to facilitate scaling and root planning

3- The presence of accessory pulp canals which communicate with the furcation area

It is believed that once the pulp is infected through the accessory canal, endo-perio communication may occur, which in turn can cause either destruction of inter-radicular periodontium or interfere with the healing response of either periodontal or endodontic procedures

4- The distance between CEJ & furcation area

5- The position of the tooth in the arch



Classification of furcation involvement

May be classified into 3 degrees depending on the extension of the destruction within inter-radicular area which include the following criteria of the involved furcation:

Class I (initial): denotes horizontal loss of periodontal tissue (PD) support not exceeding 1/3 of the width of the tooth

Class II (partial): denotes horizontal loss of (PD) tissue support exceeding 1/3 of the width of the tooth but not encompassing the total width of the furcation area

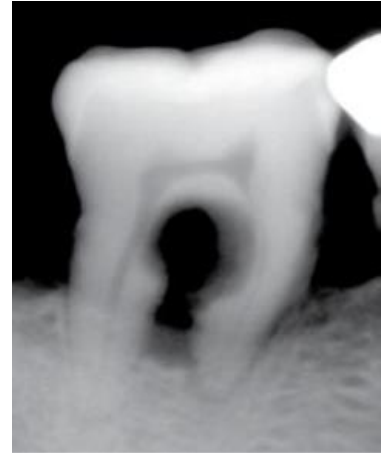Class III (total): denotes horizontal 'through and through' destruction of the PD tissues in the furcation area

- Sometimes we have class IV when the gingiva recedes apically so that the furcation opening is seen clinically

Diagnosis: the examination should comprise both clinical probing and radiographical analysis

Probing: the buccal furca of the maxillary molars and buccal and lingual furcas of the mandible

- Molars are normally accessible for examination by clinical probing by using graduated curved periodontal probe explorers or small curettes
- Special **furcation probes** are available which are rounded & have millimetre indications, these probes are called #Naber probes
- The clinical examination of furcas on the proximal tooth surfaces may be more difficult when neighbouring teeth are present, especially if the contact area between the teeth is wide, this is particularly in case of maxillary molar, in which the mesial furcation entrance is located much closer to the palatal than to the buccal tooth surface
- Thus the mesial furcation should be probed from the palatal aspect of the tooth, while the furca in the distal surface is probed from either the buccal or the palatal aspect
- In maxillary premolars, the root anatomy often varies considerably
- The roots may also harbour irregularities such as longitudinal furrows, invaginations or true furcation, which may open at varying distances from the CEJ
- The clinical examination of maxillary premolars is often difficult due to limited access for probing
- It may not always be possible to identify the presence and the degree of furcation involvement in such teeth until a flap is raised in a surgical procedure in the area



Radiological analysis

Radiographs must always be obtained to confirm findings made during probing of a furcation-involved tooth

- The radiographic examination should include both paralleling 'periapical' and vertical 'bite-wing' radiographs
- In the radiographs the location of the interdental bone as well as the bone level within the root complex should be examined
- In certain situation, the findings from clinical probing and from radiographs may occur inconsistent
- Thus the localised but extensive attachment loss which may be detected within the root complex of a maxillary molar with the use of a probe, will not always appear in the radiograph
- This may be due to the superimposition in the radiograph of the palatal root and of remaining bone
- Cone beam computed tomography (CBCT) should be used

Differential diagnosis

A lesion in the inter-radicular space of a multi-rooted tooth may be associated with problems originated from the root canal or be the result of occlusal overload

- The treatment of a furcation tooth, therefore, should not be initiated until a proper differential diagnosis of the lesion has been made

Pulp pathosis

- It may sometimes cause a lesion in the periodontal tissues of the furcation
- The radiographic appearance of such a defect may have some features in common with a plaque associated furcation lesion
- In order to differentiate between the two lesions the vitality of the affected tooth must always be tested
- If the tooth is **vital**, a plaque-associated lesion should be suspected
- If the tooth is **non-vital**, the furcation involvement may have endodontic origin
- In such case, a proper endodontic treatment must always precede periodontal therapy
- In fact, endodontic therapy may resolve the inflammatory lesion, soft and hard tissue healing may occur and furcation defect will disappear

Trauma from occlusion

Forces elicited by occlusal interferences such as bruxism and clenching, may cause inflammation and tissue destruction or adaptation within the inter-radicular area of a multi-rooted tooth

- In such a tooth, the radiolucency may be seen in the radiograph of the root complex
- The tooth may exhibit increased mobility
- Probing, however, fails to detect an involvement of the furcation
- In this particular situation, occlusal adjustment must always precede periodontal therapy

Prognosis

Maxillary first molar in addition to **maxillary** and **mandibular molars** are the teeth with multiple roots

- Maxillary first premolar often shows fusion of the roots and the furcation area may be located very much apically and also the roots of the maxillary first premolars are placed buccally and palatally with furcation opening in a mesio-distal direction
- For these reasons, furcation involvement in maxillary first premolar has a poor prognosis
- In the case of **maxillary molars**, furcation may open buccally, mesially and distally because of the three roots
- Since access from proximal areas is difficult for plaque control, prognosis of furcation involvement in maxillary molars is not promising
- Mandibular molars have two roots, placed mesially and distally and the furcation opens buccolingually
- The roots are usually divergent especially in mandibular first molars, as a result prognosis of furcation involvement in mandibular molar (especially the first molar) is promising

Treatment of furcation involvement

Degree I: scaling and root planning
furcation plasty

Degree II: furcation plasty
Tunnel preparation
Root resection& tooth hemi-section
Guided tissue regeneration
Tooth extraction

Degree III: Tunnel preparation
Root resection & tooth hemi-section
Guided tissue regeneration
Tooth extraction

References

- Clinical Periodontology and Implant Dentistry By Jan Lindhe
- Colour Atlas of Dental Medicine and Periodontology

Treatment of furcation involvement

Treatment of advanced forms of periodontal disease frequently includes surgical procedures

Objectives of treatment of furcation involvement

The general objects of these procedures are:

- 1- To obtain visibility and access to the root surfaces for proper professional debridement and elimination of the microbial plaque of the affected surfaces of the root complex
- 2- To eliminate the pathologically deepened pockets
- 3- To establish of an anatomy and morphology of the affected surfaces that facilitates proper self-performed plaque control

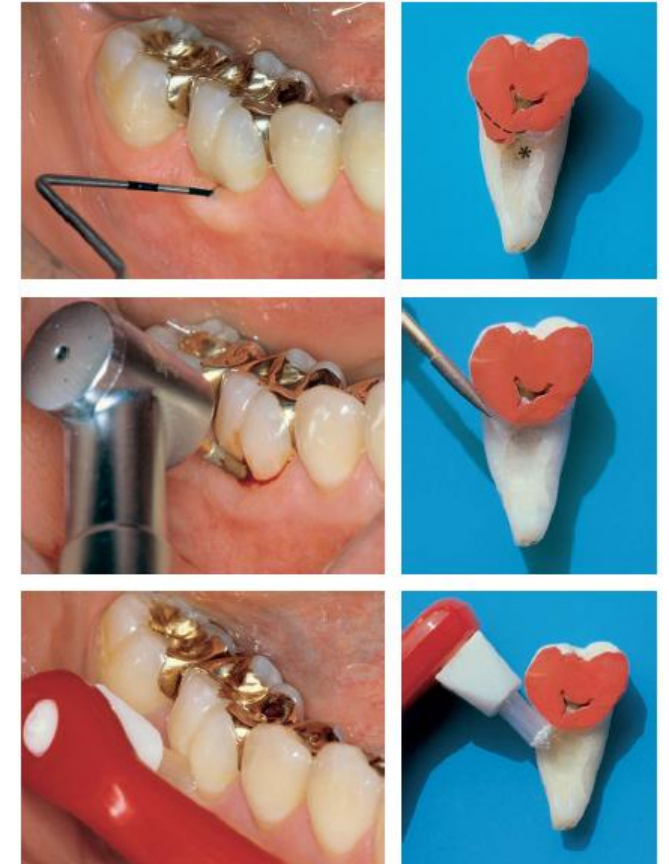
Degree I

1- Scaling and root planning : is the removal of hard and soft bacterial deposits from the tooth and root surfaces in order to simplify the self-performed plaque control measures

2- Furcation plasty: is the therapeutic measure that is preferably used in the treatment of advance degree I & II involvement. It includes the following procedures:

- a) Reflection of a mucoperiosteal flap to obtain a proper access to the inter-radicular area
- b) Removal of hard and soft bacterial deposits and inflammatory soft tissue from the furcation area
- c) Odontoplasty: removal of part of tooth substance in the furcation area in order to widen a narrow entrance of the furca area and to reduce the horizontal depth of the lesion
- d) Osteoplasty: recontouring of bony defects in the furcation area
- e) Reposition and suturing of the flap

Aims of furcation plasty: is the removal of all the soft and hard materials and then establishment a good area for self-performed plaque control measures



Common side effects associated with recontouring a tooth by furcation plasty

- 1- Hypersensitivity of the area
- 2- Root surface caries
- 3- More destruction of the periodontal tissue

Degree II

- 1- Furcation plasty
- 2- Tunnel preparation
- 3- Root resection & tooth hemisection
- 4- Tooth extraction
- 5- Guided tissue regeneration

Note: scaling and polishing is made in the treatment of any degree of furcation involvement and not only for degree I

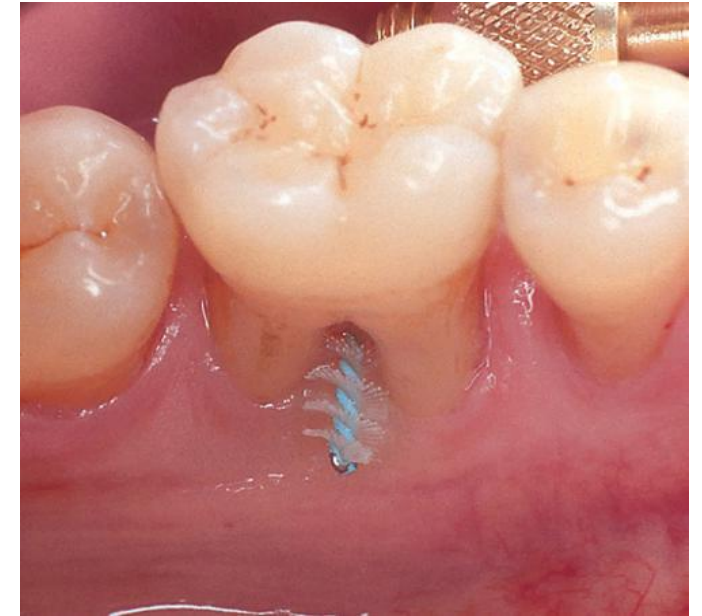
Tunnel preparation: used in cases of degree II & in most of degree III furcation involvement

- It is a surgical exposure of the entire furcation area
- Buccal and lingual flaps are elevated, root surface is scaled and planned, bone is recontoured
- Removing all infected materials, in the bone, bottom of the pocket and on the sides of the roots
- Need for odontoplasty and osteoplasty then either left exposed or covered by tissue depending on the patient whether maintaining high level of plaque control (because of high risk of root caries)

- This procedure is applied mostly to lower molar bifurcation area
- Provide good space for spiral brush to pass freely through the furcation from the buccal and lingual side

This procedure is more valuable in the treatment of lower molars because:

- 1- Short root trunk
- 2- Wide separated angle
- 3- Long divergence between mesial and distal root

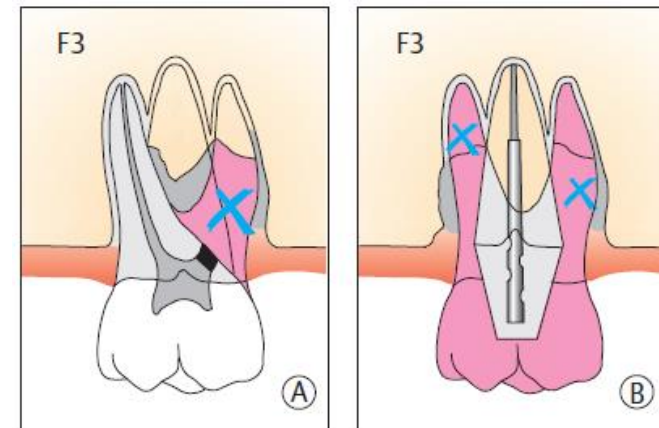


Root resection/separation, tooth division and hemisection

Root separation: involves in the section of the root complex and the maintenance of all roots

Root resection: is the treatment of choice in case of deep degree II and III involvement and includes the removal of one or more roots from a multi-rooted tooth to allow access to the furcation area for cleaning

- After raising buccal and palatal flaps sectioning should start in the affected furcation and its path may be planned by passing a blunt probe through the space from buccal to palatal side
- The cut is made with a tapered diamond bur cooled by sterile water
- A wide enough space should be made to elevate the root, taking care not to remove too much substance from the tooth

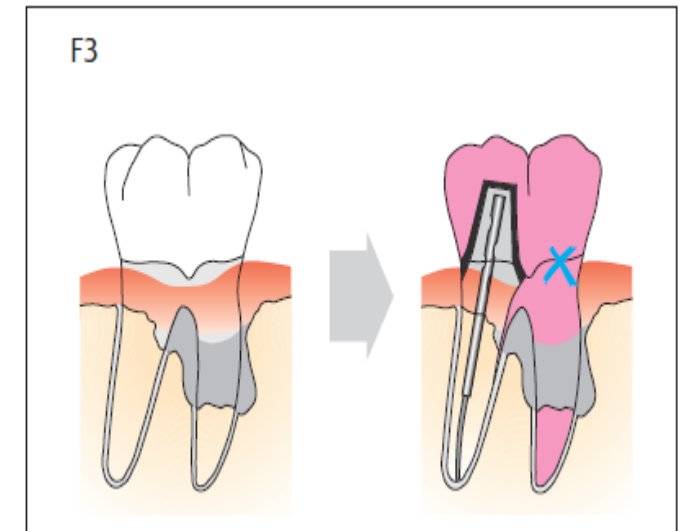
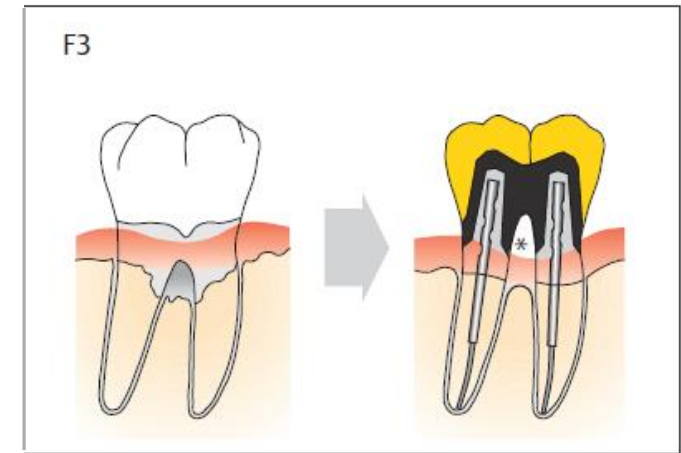


Tooth division: is indicated for extensive furcation involvement of lower molars where bone loss around both roots is similar

- In this procedure, the tooth is completely divided by extending a cut from the roof of the furcation through the crown after raising a buccal and lingual flaps
- Each half of the tooth is reshaped into a single-rooted tooth and will subsequently prepared to receive a crown
- In this way a two-rooted mandibular molar is converted into two single rooted-teeth

Hemisection is indicated for furcation involvement of **lower molars** where there is extensive bone resorption around one of the roots

- It must be ensured that adequate restoration of the remaining half of the crown is possible before embarking on this procedure
- A buccal and lingual flaps are raised, the sectioning process is begun at the roof of the furcation, extending upwards to divide the tooth
- The remaining root is scaled and planned
- The remaining half of the crown is carefully contoured and smoothed and the flaps are repositioned to eliminate any pocketing
- After healing, the tooth should be crowned, usually forming part of the bridge to replace the missing portion
- Root resection and hemisection should be preceded by endodontic treatment for the root that will be retained in the place
- A small cavity is made at the entrance of the canal of the root to be removed and packed with amalgam to produce a permanent seal at the point of amputation



Tooth Extraction

The indications for tooth extraction are:

- 1- When the destruction of periodontium has progressed to such a level that no root can be preserved
- 2- When the maintenance of the affected tooth will not improve the overall treatment
- 3- When the treatment of the furcation involved tooth will not result in a condition which can be properly maintained by self performed plaque control measures

Failure in furcation therapy could be due to

- 1- Inadequate plaque control
- 2- Bad root resection technique
- 3- Improper restorations
- 4- Endodontic failures
- 5- Cracked roots
- 6- Root caries

- The **best prognosis** is from root resection and hemisection while the **least prognosis** is the tunnel preparation because the patient cannot remove the plaque completely from the central part of the furcation and will end up with pulp involvement

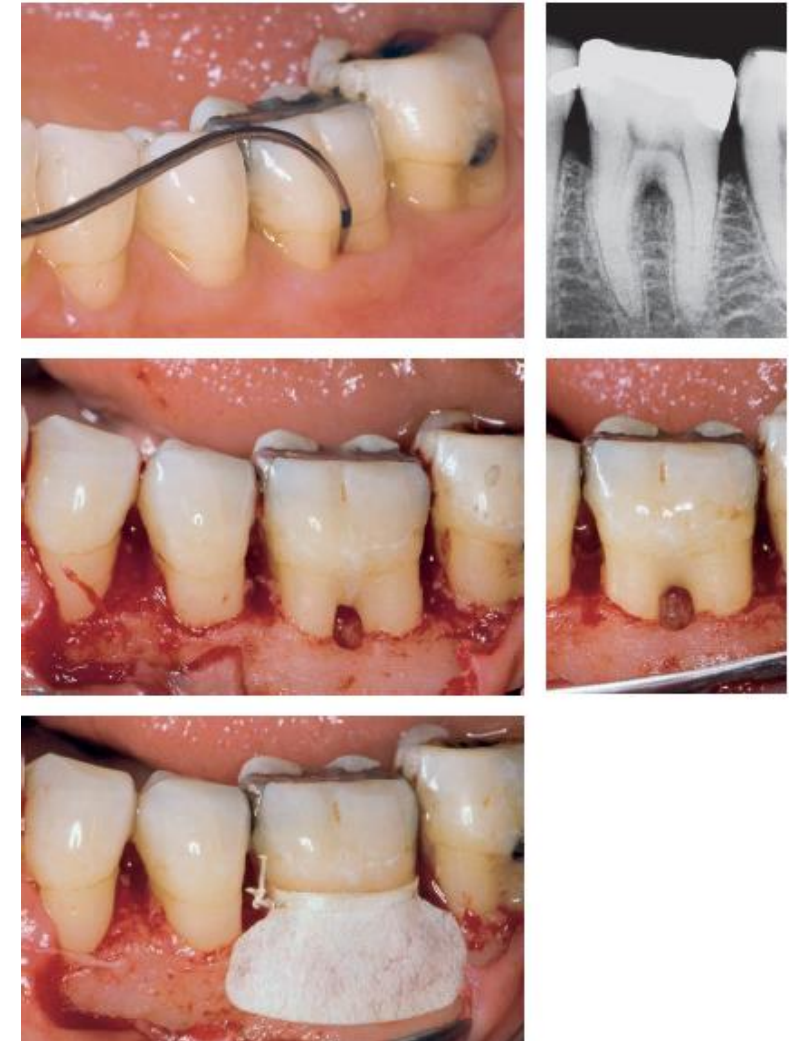
Regeneration of the furcation defects

Guided tissue regeneration (GTR) and bone grafting

GTR techniques have been successfully used to treat class II furcation involvement in mandibular molars

- The aim of this procedure is the formation of new connective tissue attachment consisting of periodontal ligament fibres embedded into bone and cementum
- Alveolar bone and cementum have good ability for regeneration, provided the necessary cell types (mesenchymal stem cells) and cell signals

In GTR technique, a barrier membrane is adapted to fit over the defect and the root of the tooth in order to guide the fibroblast cell of PDL to contact the root surface during healing and prevent other cells of oral epithelium of gingival connective tissue from contacting the root surface so that it leads to a new connective tissue attachment



There are two types of GTR:

- 1- Non-resorbable membrane
- 2- Bioresorbable membrane

Bone substitute materials or bone grafting

Types of bone graft:

A- Autogenous bone grafting: grafts transferred from one position to another within the same individual

B- Allografts: grafts transferred between genetically dissimilar members of the same species, such as freeze dried bone

C- Xenografts: grafts taken from a donor of another species such as bovine (from cow) or porcine (from pig)

D- Alloplastic materials: synthetic or inorganic implant materials which are used as substitutes for bone grafts, such as hydroxyapatite and tricalcium phosphate

Combination of GTR with the use of bone grafts have been shown to have some advantages over either technique used alone

- Clinical studies found a significantly greater gain of mean probing attachment with the combination compared to GTR alone

References

- Clinical Periodontology and Implant Dentistry By Jan Lindhe
- Colour Atlas of Dental Medicine and Periodontology

Epidemiology of periodontal disease

Introduction

The term epidemiology is of Hellenic origin, it consists of the preposition '**epi**' which means **among** or **against** and the noun **demos** means **people**

Epidemiology: defined as the study of the distribution of disease or a physiological condition in human populations and of the factors that influence this distribution

Epidemiologic measures of disease

Incidence is defined as the rate of occurrence of a new disease in a population during a **given period of time**

Prevalence is defined as the proportion of people affected by the disease at a specific time point such as a **cross-sectional survey**

Epidemiology has many purposes

- 1- To determine the amount and distribution of a disease in population
- 2- To investigate the causes of the disease
- 3- To apply this knowledge to control the disease
- 4- To evaluate the need and the effectiveness of health services and the need of man power

Epidemiologic study design

1. Observational: which represents most of epidemiologic studies. in these studies researchers observe natural occurrence in the population

The most common observational studies are:

- 1- Cross-sectional studies
- 2- Cohort studies
- 3- Case control studies

2. Experimental studies

Cross-sectional studies

- In cross-sectional studies the presence or absence of disease and the characteristics of the members of a population are measured at **a time point**
- These studies are useful for providing prevalence data on a disease, comparing the characteristics of persons with and without a disease and generating hypotheses regarding the aetiology of the disease

Cohort studies

- Cohort studies unlike cross-sectional studies, cohort studies subjects over time and the purpose of a cohort study is to determine whether an exposure or characteristic are associated with the development of a disease or condition at the beginning of the study, all subjects must be free from the disease of interest. Subjects are classified into **exposed** and **unexposed** groups and then followed over time and monitored for the development of the disease

Case-control studies

- In case control studies, persons with the disease (cases), persons without the disease (control)
- The proportion of exposed persons would be expected to be greater among the cases than the controls
- Because case-control studies do not follow subjects over time they require fewer resources and can be conducted more quickly than cohort study

Epidemiological indices

Indices are methods for quantifying the amount and severity of diseases or conditions in individuals or proportions

Index is a numerical value describing the relative status of population on a graduated scale with definite upper and lower limit which is designed to permit and facilitate comparison with other population, classified by the same criteria and method

Types of indices:

- 1- Reversible indices measure the disease in which no damage occur and the condition is reversible such as gingivitis
- 2- Irreversible indices measure destructive disease and damaging conditions such as periodontitis
- 3- Other indices that shows both reversible and irreversible indices such as periodontal index (PI) by Russell 1956

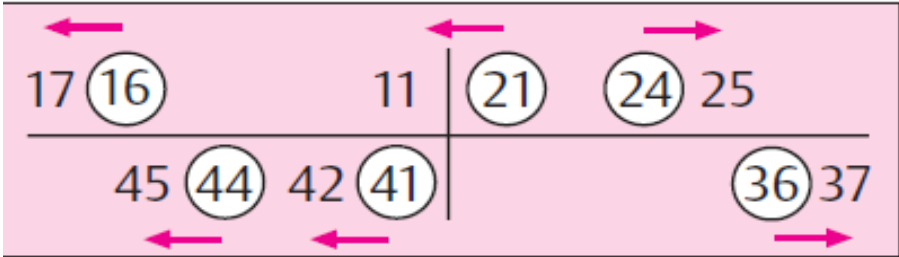
Requirements of an epidemiological index

- 1- Easy to use
- 2- Permit the examination of many people in a short time
- 3- Define the clinical conditions objectively
- 4- Can be reproducible in assessing a clinical condition when used by one or more than one examiners
- 5- Can be analysed statistically

Periodontal index (P.I) by Russel 1956

- 0 – Tooth with healthy periodontium
- 1- Tooth with gingivitis around only part of the tooth circumferences
- 2- Tooth with gingivitis encircling the tooth
- 6- Pocket formation
- 8- Loss of function due to excessive tooth mobility

Periodontal disease index (PDI) by Ramfjord 1959



Grade	
0	Inflammation-free. No gingival alterations
Gingiva	
1	Mild to moderate gingivitis at isolated sites on the gingiva surrounding the tooth
2	Mild to moderate gingivitis surrounding the tooth
3	Severe gingivitis, visible erythema, hemorrhage, gingival ulcerations
Periodontium	
4	Attachment loss to 3 mm, measured from the CEJ
5	3–6 mm attachment loss
6	Attachment loss greater than 6 mm

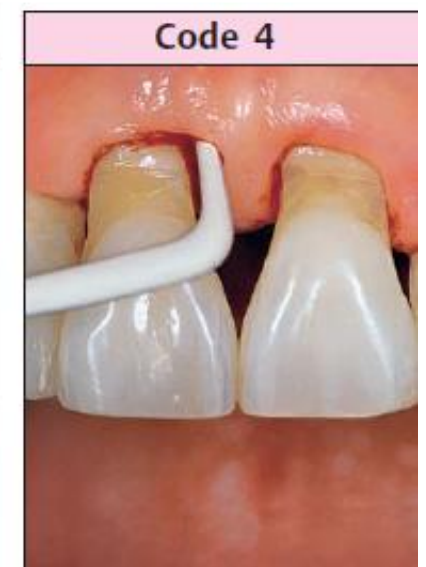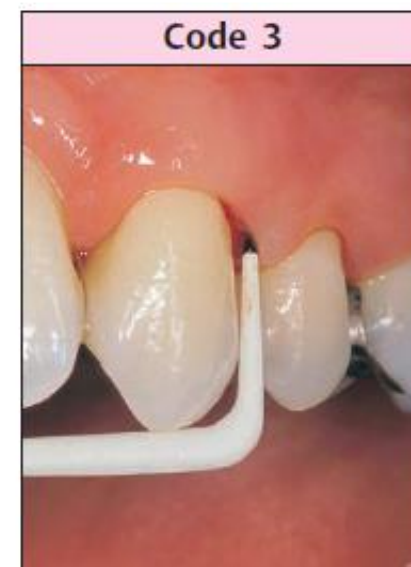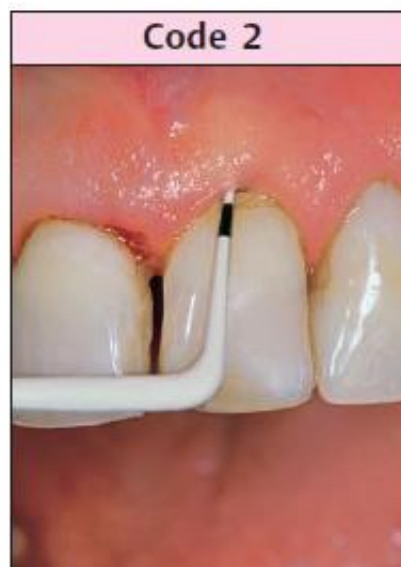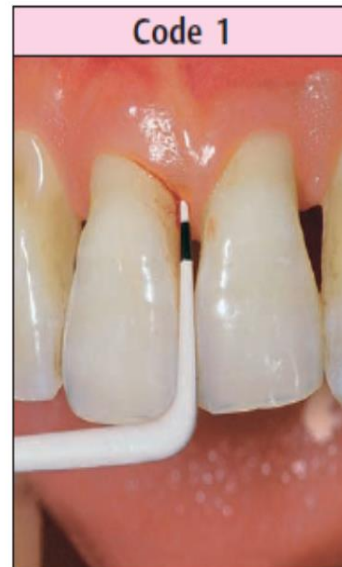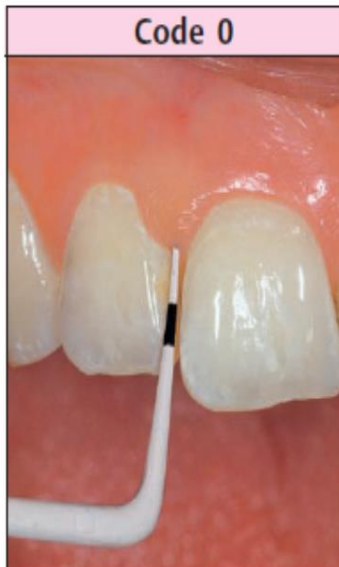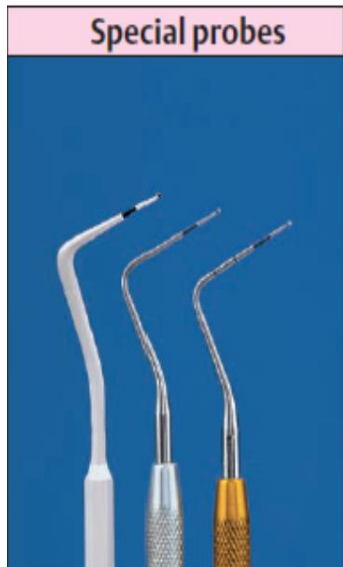Mobility index by Miller 1950

- 0 - No detectable movement when force is applied
- 1- Crown to the tooth moves up to 1mm in any direction
- 2- The movement is more than 1mm in any direction
- 3- Tooth that can be depressed or rotated in their socket

Community periodontal index for treatment need by Ainamo et al (1982)

- It studies the most often employed index. The major difference between the **CPTIN** and the other indices is that it determines not the severity of gingivitis and periodontitis but also provide data concerning the extent of the therapy that is necessary and determine the manpower
- The examination is performed with a special probe, which is known as **CPI** probe with 0.5mm ball tip with black band between 3.5mm and 5.5mm (1987) and ring at 8.5mm and 11.5mm from ball tip for measurement of loss of attachment

- 0 → Healthy → No treatment need
- 1 → Bleeding on probing → Oral hygiene instruction (OH)
- 2 → Supra and /or subgingival calculus → 1 + Calculus removal
- 3 → Shallow pockets up to 5mm → 1 + 2 + root planning
- 4 → Deeper pockets from 6mm → 1+ 2+ 3+ complex treatment



Estimation of man power

0	No treatment need	0 min
1	Oral Hygiene instruction	15 min
2	1 + calculus removal	20 min
3	1+2+ root planning	30min
4	1+2+3+ complex treatment	60min

References

- Clinical Periodontology and Implant Dentistry By Jan Lindhe
- Colour Atlas of Dental Medicine and Periodontology

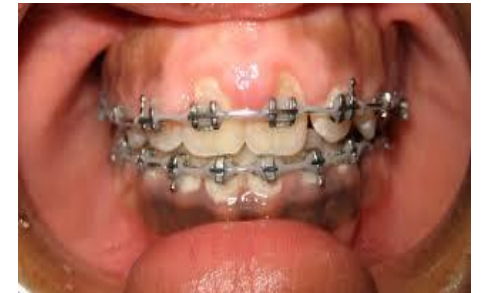The relation of periodontics with different dental disciplines

Ortho-perio interaction

- Plaque represents the key element in orthodontic management of adult patients with periodontal disease, which needs to be eliminated or reduced to get rid of gingival inflammation
- This will need a great oral hygiene instruction
- Appliance construction design and periodontal check up through out the treatment period

The orthodontic appliance should have the following properties

- 1- It must provide stable anchorage
- 2- It does not cause tissue irritation
- 3- Aesthetically acceptable
- 4- Less plaque accumulation (the simplicity of the design such as avoid hooks and elastomeric rings, which is more plaque attractive than steel ties.



Management of patient with orthodontic appliance:

- Oral hygiene instruction and motivation after placement of ortho-appliance
- Periodic periodontal recall, which would include:
 - 1- Recording the probing depth
 - 2- Mobility
 - 3- Bleeding on probing
 - 4- Gingival recession
 - 5- Bone level
- **Professional scaling** may be indicated during active treatment especially in case of intrusion of elongated maxillary incisors
- If there is no way to excellent oral hygiene, ortho treatment should be terminated
- After appliance removal re-instruction to oral hygiene measures should be given to avoid subsequent side effects as gingival recession

Periodontal-Restorative interaction

Margins of restoration

The location of restorative margins is determined by many factors

- 1- Aesthetic concerns
- 2- Need to increase retention form
- 3- Refinement of pre-existing margins
- 4- Root caries
- 5- Cervical abfraction
- 6- Root sensitivity

Margin placement and the biological width

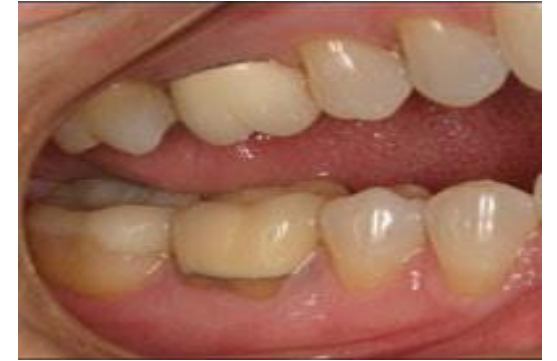Supra-gingival

Equi-gingival

Sub-gingival

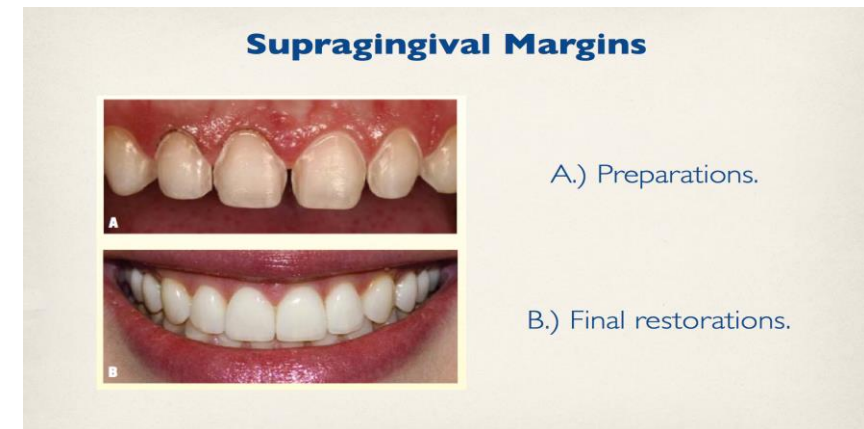Supragingival margin

- Least impact on the periodontium
- Preparation of the tooth and finishing of the margin are easiest
- Duplication of the margins with impressions can be easily done
- Fitness and finishing of the restoration and removal of excess material are easy
- Easy way to verify the marginal integrity of the restoration



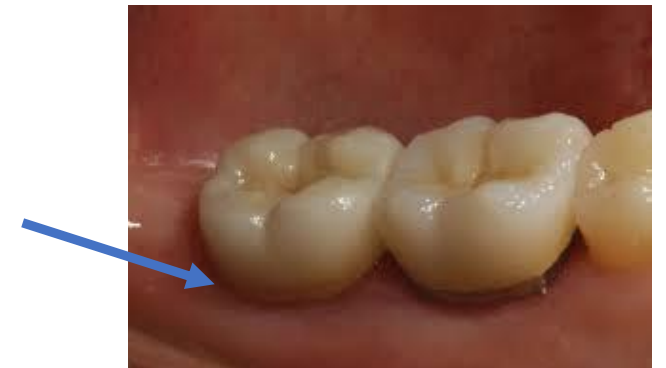Equi-gingival margin

Retains more plaque than supra and sub gingival margins, therefore it results in greater gingival inflammation



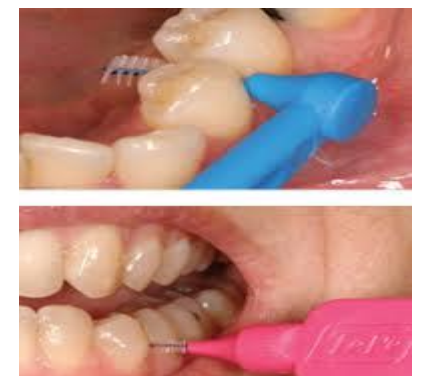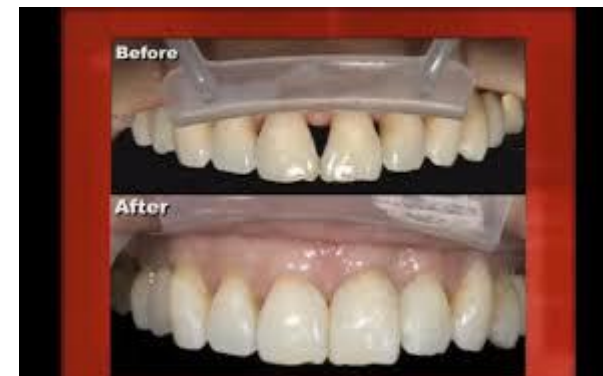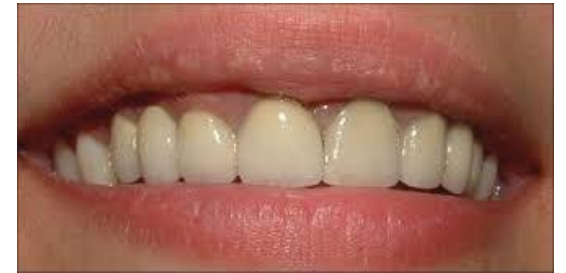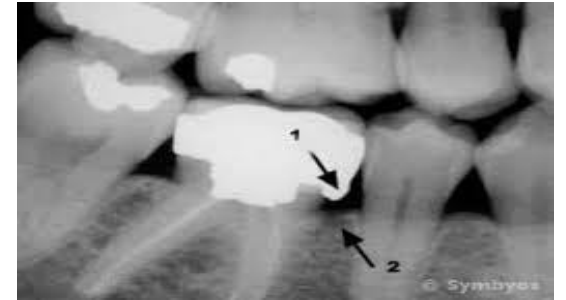
Subgingival margin

- Greatest biological risk
- Not as accessible as **supra** or **equi** for finishing procedures



Overcontoured restoration

- When the gingiva contacts a flat (noncontoured) tooth surface, there is a tendency to develop a thick free gingival margin
- Overcontouring of restorations or faulty placement of contour is a much greater hazard to periodontal health than a lack of contour since supra- and subgingival plaque accumulation may be enhanced by overcontoured margins
- The greater the convexity, the more difficult is to remove the plaque
- All the margins if possible would be better at supragingival especially in the posterior area
- However, for aesthetic reasons, in case of anterior region, the margins should be kept with the gingival margin
- Buccal and lingual surfaces must not be overcontoured
- The width of **the embrasure** area should be restored and matched to the size of the particular interdental cleaning device recommended to the patient



Interproximal contacts

- There should be a positive contact relation between one tooth with another in both dental arch
- The contact points should be located incisal or occlusal and buccal side

Restorative materials

Restorative material themselves are not injurious to the periodontal tissues

- The surface of restorations should be very smooth in order to limit plaque accumulation. Resins are highly polishable but have strength deficiency in addition to having porosity and wear
- Glass ceramics and zircon offer a clear advantage over any other type of restorative materials in the maintenance of the gingival health

Prosthetic and periodontic interaction

- A special instruction and motivation for the patients having prosthodontics to get a proper oral hygiene
- It is recommended to use chrome-cobalt partial denture rather than acrylic one in all cases except immediate one

Endodontic- periodontic lesions

Anatomic considerations

- There is an intimate relationship between the periodontium and pulpal tissues
- As the tooth develops and the root is formed, 3 main avenues for communication are created
 - 1- Apical foramen
 - 2- Lateral and accessory canals
 - 3- Dentinal tubules

Additional avenues of communication between the pulp and periodontium

- Developmental malformations, such as platogingival grooves of maxillary incisors, which are usually begin at the central fossa, cross the singulum and extend apically with varying distances
- Perforations which may result from extensive carious lesions, resorption or by operator error
- Vertical root fractures which can produce deep periodontal pocketing and localised destruction of alveolar bone. The fracture side provides a portal of entry for irritants for root canal to the PDL

Differential diagnosis of endon-perio lesions

Some classification system of this relation:

- Primary endodontic disease
- Primary periodontal disease
- Primary endo with secondary perio
- Primary perio with secondary endo
- True combined lesions

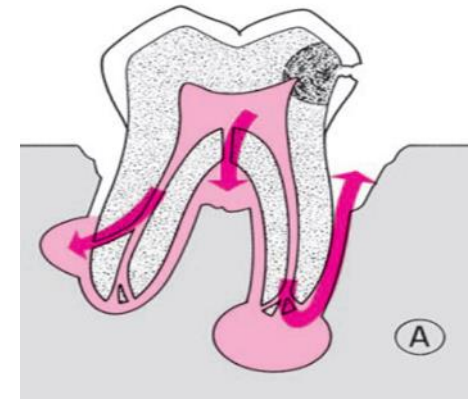
Primary endodontic disease

- Endodontic lesions resorb the bone in an apical and destroy and lateral directions the attachment apparatus adjacent to the involved tooth
- It is widely possible for a chronic periapical lesion to drain through the PDL and sometimes to the gingival sulcus. In this case the clinical presentations mimic the presence of periodontal abscess or a deep periodontal pocket

- For diagnostic purposes, it is imperative trace the sinus tract by inserting a gutta-percha cone and exposing one or more radiographic x-rays to determine the origin of the lesion
- The sinus tract of endodontic origin is readily probed down to the tooth apex, where no increased probing depth would be otherwise existing around the tooth
- Primary endodontic disease will heal following a proper root canal treatment

Primary endo with secondary perio

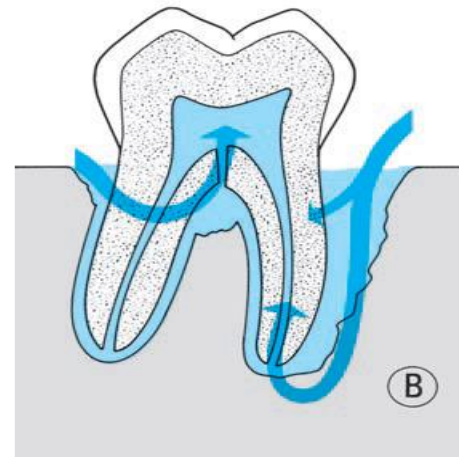
- Starts by dental caries, causing pulpitis and then flare up to periodontal region
- This may happen with the time, as a suppuration of primary endodontic disease when remains untreated and may become secondarily involved with periodontal breakdown
- Plaque forms at the gingival margin of the sinus tract and leads to a plaque-induced periodontitis in the area
- The treatment and prognosis are now different than teeth, having endo or perio disease



- The tooth here required both endodontic and periodontal treatments
- In case the endo treatment is adequate, the prognosis depends on the severity of the plaque-induced periodontitis and the efficacy of perio treatment

Primary perio with secondary endo

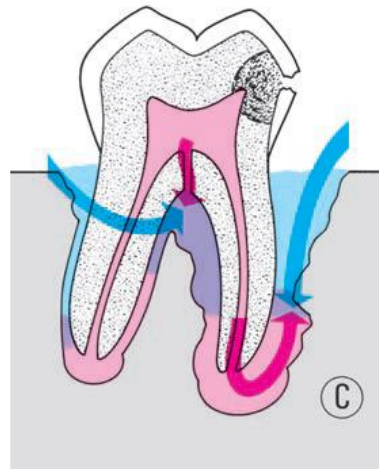
- Caused by periodontal pathogens
- It is a result of the progression of chronic periodontitis apically along the root surface
- Pulp tests yield a clinically **normal pulpal** reaction (vital pulp)
- The prognosis depends on the stage of periodontal disease
- The apical progression of the periodontal pocket continues until the apical tissues are involved
- The pulp may become necrotic as a result of infection, entering via the apical foramen



- In single rooted teeth the prognosis is usually poor, as the periodontal breakdown is very severe, which leads to tooth extraction
- In molar teeth, the prognosis may be better, since not all the roots may suffer from the same loss of periodontal support. Root resection may be considered as an alternative treatment
- In unusual cases, the treatment of periodontal disease (when removing the necrotic cement), lateral canals and dentinal tubules may be opened to the oral environment by scaling, root planning and surgical flap procedures

True combined disease

- It occurs less frequent than other endo-perio problems
- It is formed when an endodontic disease progressing coronally and join with an infected periodontal pocket, progressing apically
- The degree of attachment loss in this type of lesion is large and the prognosis is poor, particularly for single-rooted teeth



Diagnosis

- A thorough clinical and radiographical examination is mandatory for developing a proper diagnosis
- Data collection must include:
 - 1- Periapical radiographs, panoramic and cone beam computed tomography (CBCT)
 - 2- Pulp vitality test
 - 3- Percussion
 - 4- Palpation
 - 5- Pocket probing
 - 6- Sinus tracking
 - 7- Cracked tooth testing

References

- Clinical Periodontology and Implant Dentistry By Jan Lindhe
- Colour Atlas of Dental Medicine and Periodontology

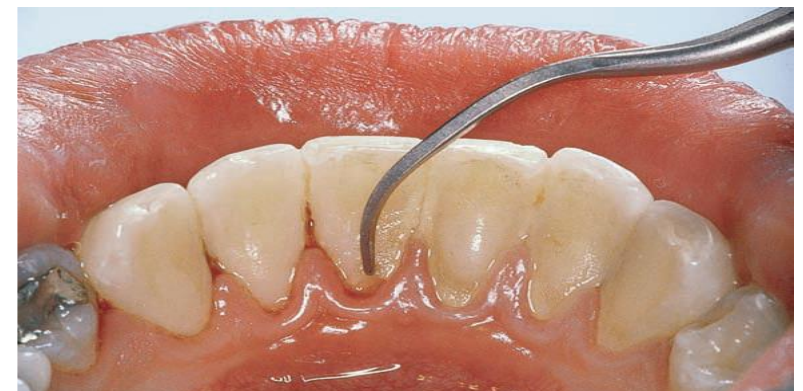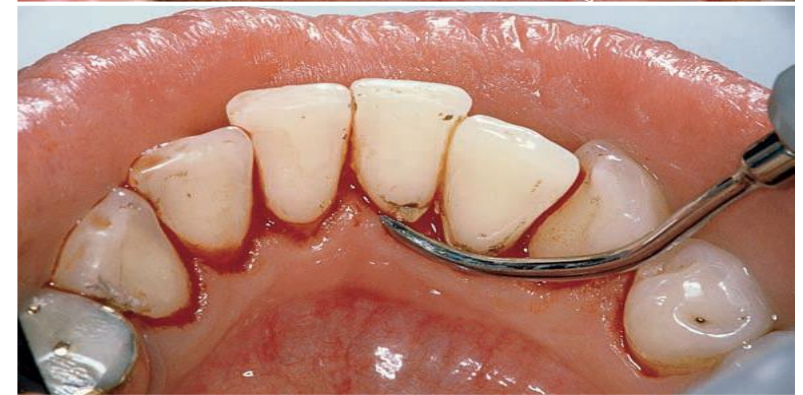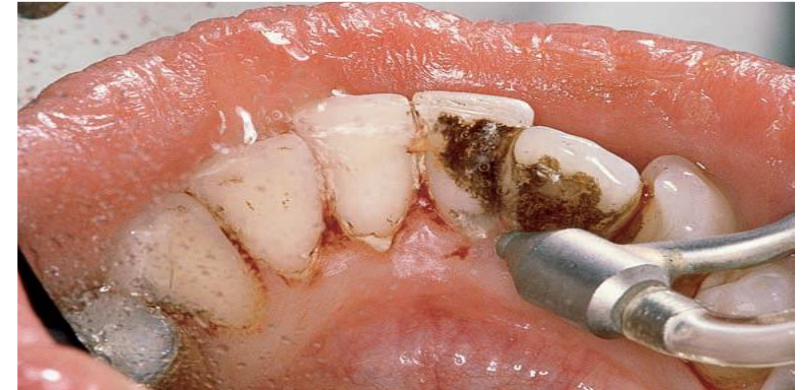Periodontal surgery

Is any surgical procedure used to treat periodontitis or modified the shape of the periodontium

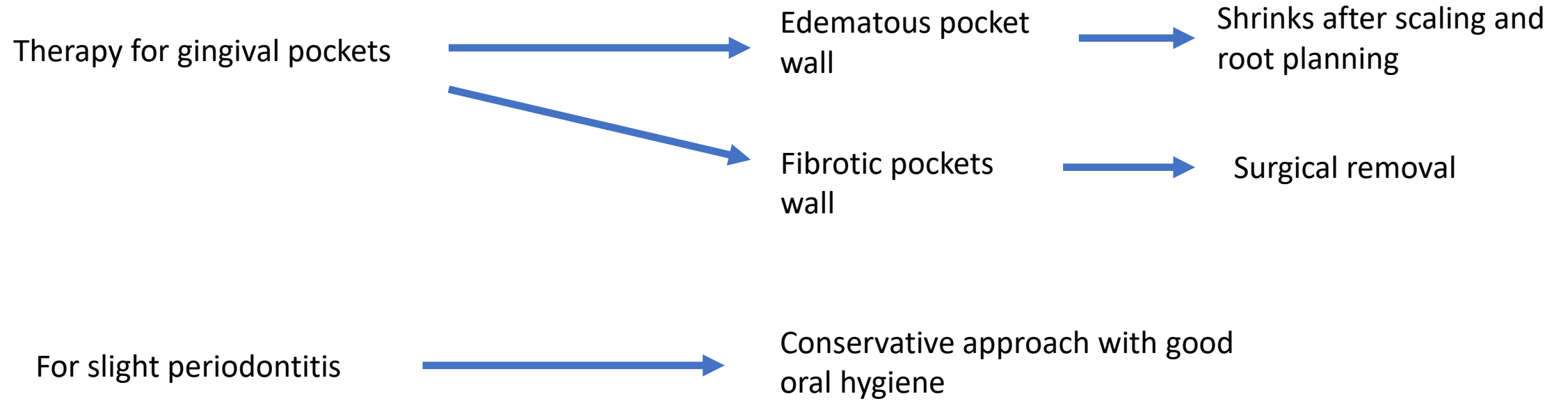
Surgical pocket therapy

Re-evaluation after phase 1 therapy

All patients should be treated initially with scaling and root planning and the final decision on the need for periodontal surgery should be made after evaluation of the effects of phase 1 therapy no less than 1-3 months after completion of phase 1 therapy



Approaches to specific pocket problems



Approaches to specific pocket problems

Moderate to severe periodontitis
in anterior sector



- Scaling and root planning
- The papilla preservative flap or sulcular incision flap if surgery is indicated

Moderate to severe periodontitis
in posterior sector



Surgery is frequently indicated

Critical zones in pocket surgery

1- Soft tissue pocket wall: thickness, topography and persistence of inflammatory changes in the wall

2- Tooth surface: the accessibility of the root surface to instrumentation

3- Underlying bone: bone craters, horizontal or angular bone loss are important criteria in the selection of the treatment technique

4- Attached gingiva: presence or absence of adequate area of attached gingiva

General principles of periodontal surgery

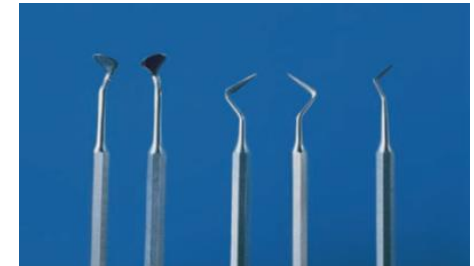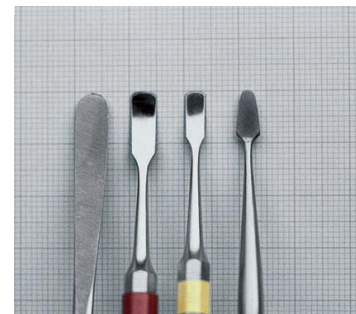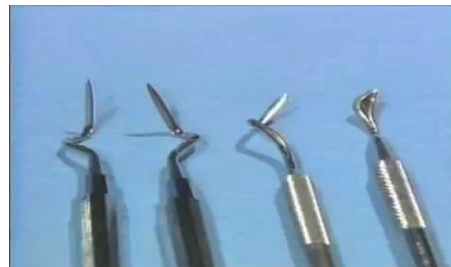- All surgical procedures should be very carefully planned
- The patient should be adequately prepared, psychologically and practically for all aspects of the intervention

Principles

1. Preparation of the patient 2. Emergency equipment 3. Measures to prevent transmission of infection 4. Sedation and anaesthesia 5. Tissue management 6. Scaling and root planning 7. Haemostasis 8. Periodontal dressing 9. Instructions after surgery 10. First post operative week 11. Removal of the pack 12. Management of post operative pain

Surgical instruments

- 1- Excision and incisional instruments
- 2- Surgical curettes and sickles
- 3- Periosteal elevators
- 4- Surgical chisels
- 5- Surgical burs and files
- 6- scissors
- 7- Haemostats and tissue forceps

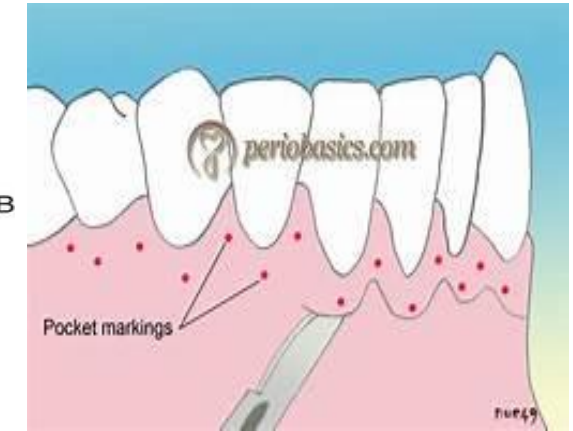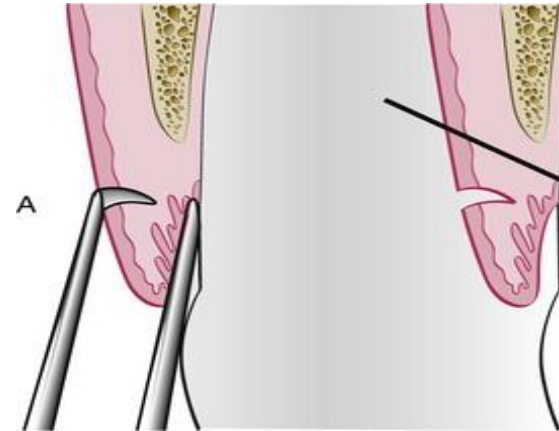


Types of incisions in periodontal surgery

Horizontal incisions

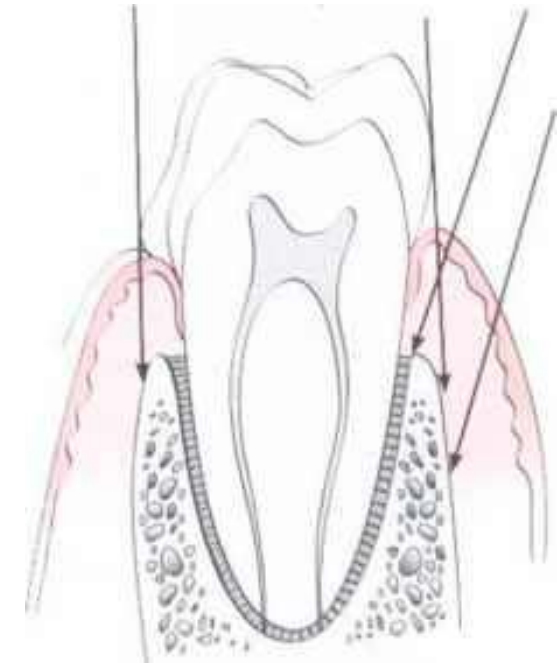
A- External bevel incision (gingivectomy incision)

- Bevelled at 45 degrees to the tooth surface
- Kirkland knife is used for this incision



B- Internal bevel incision (the basic incision in periodontal flap surgery)

- It starts at a distance (1-2mm) from the gingival margin and is aimed at the bone crest. The no. 15 surgical blade is used
- The initial incision for the reflection of a periodontal flap
- Reverse bevel incision, because its bevel is in reverse direction from that of the gingivectomy incision



C- Crevicular incision

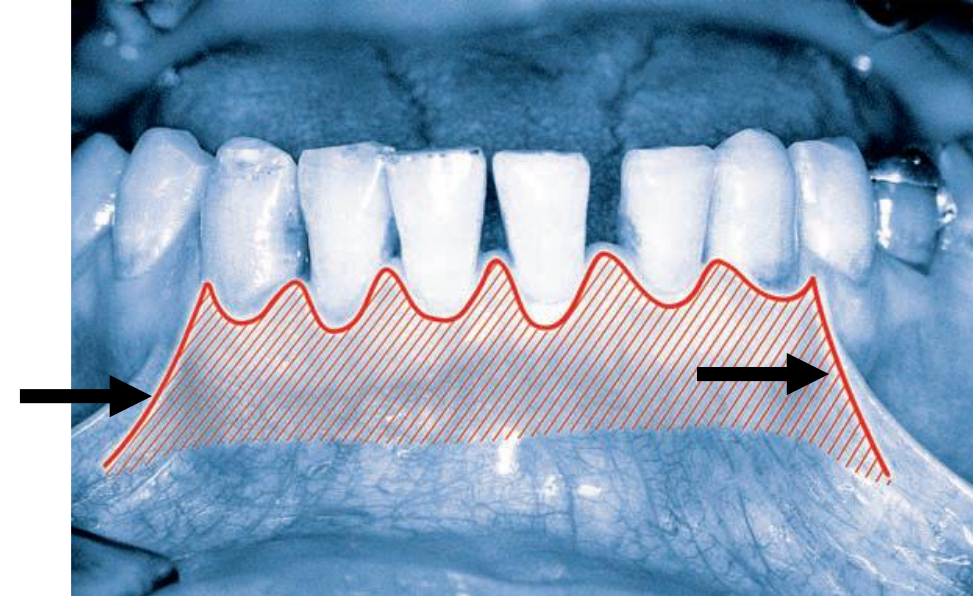
- Second incision, is from the base of the pocket to the bone crest
- Scalpel no. 12D is usually used
- This incision results in a V-shaped wedge of tissue containing of lateral wall of pockets, junctional epithelium and connective tissue fibres between the base of the pocket and crest of the bone

D- Interdental incision

- Orban knife is used for this incision

2- Vertical incision

- Oblique releasing incision: can be used on one or both ends of the horizontal incision
- Vertical incisions at the both ends are necessary if the flap is to be apically displaced.
- Vertical incision must extend beyond the mucogingival line to reach the alveolar mucosa, this allows for release the flap and to be displaced
- Generally, vertical incisions in the lingual and palatal areas should be avoided unless it is necessary

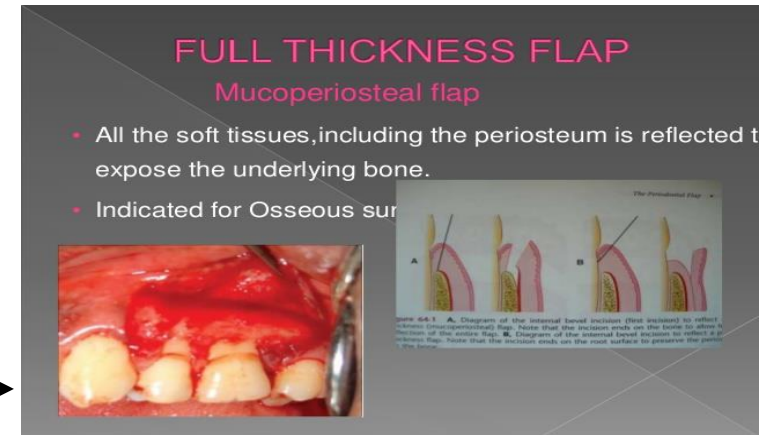


Elevation of the flap

1- Blunt dissection

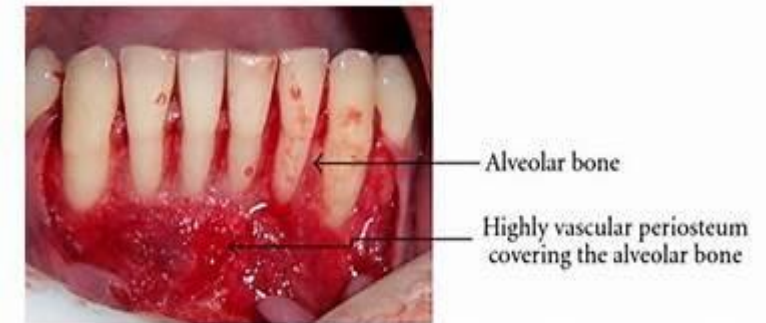For full-thickness flap reflection:

- A periosteal elevator is used to separate the mucoperiosteum from the bone by moving it mesially, distally and apically until the desired reflection is accomplished



2- Sharp dissection: is necessary to reflect a partial thickness flap

- A surgical scalpel no.15 is used



Gingival surgical techniques

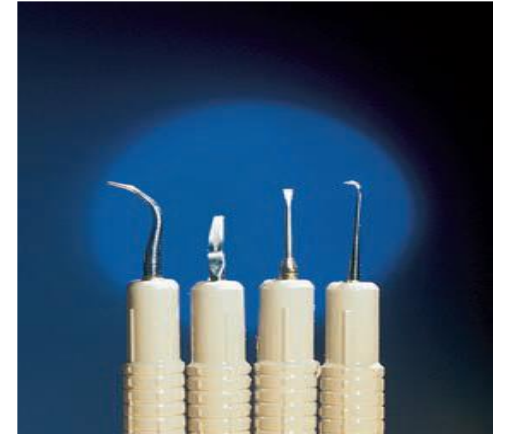Gingival curettage: scraping of the gingival wall of a periodontal pocket to separate diseased soft tissue

Subgingival curettage: refers to the procedure that is performed apical to the epithelial attachment, serving the connective tissue attachment down to osseous crest

Inadvertent curettage: that is done unintentionally during scaling and root planning

Ultrasonic curettage

- Recommended for gingival curettage. It is effective for debridement of the epithelial lining of periodontal pockets
- This results in a narrow band of necrotic tissue (micro cauterization) , which strips off the inner lining of the pocket
- According to some investigators, when they found ultrasonic instruments is to be as effective as manual instruments for curettage, but resulting in less inflammation and less destruction to the underlying connective tissue than manual instruments

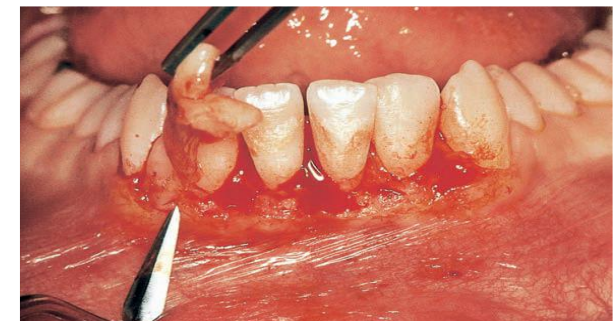
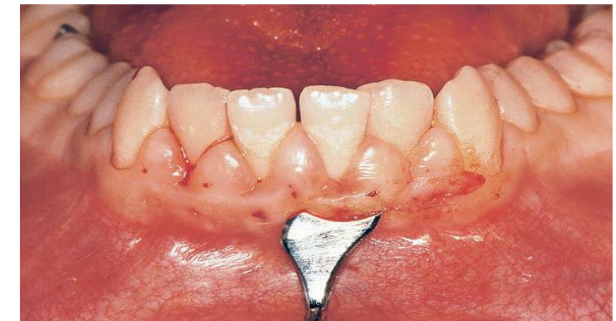
Gingivectomy

Means excision of the gingiva (performed to eliminate false periodontal pockets)

Objectives

- Removing the false pockets, calculus and smoothing of root surface
- Creating a favourable environment for gingival healing and restoration of a physiologic gingival contour



Gingivoplasty

- Is a reshaping of the gingiva to create physiologic gingival contours in the absence of pockets
- Can be done by means of a periodontal knife, scalpel, rotary coarse diamond stones or electrode

Indications

- 1- Elimination of supra-bony pockets, regardless of their depth, if the pocket wall is fibrous and firm
- 2- Elimination of gingival enlargements
- 3- Elimination of suprabony periodontal abscesses

Contraindications

- 1- In case of need for bone surgery or examination of bone shape and morphology
- 2- Situations in which the bottom of the pocket is apical to the mucogingival junction
- 3- Aesthetic considerations, particularly in the anterior maxilla

Technique

Step-1: after anesthetizing the area indicated for surgery, the pockets on each surface are explored with a periodontal probe

Step-2: Periodontal knives (Kirkland knives) are used for incision on the facial and lingual surfaces and on the distal to the terminal tooth in the arch while Orban periodontal knives are used for interdental incision

- The incision starts apical to the points marking the course of the pockets and it is directed coronally to a point between the base of the pocket and the bone crest
- The incisions should be bevelled at 45 degrees to the tooth surface and should be in line with the normal scalloped pattern of the gingiva

Step-3: Removing the excised pocket wall and cleaning the area

Step-4: carefully curette out the granulation tissue and remove any remaining calculus and necrotic cement and make a smooth and clean root surface

Step-5: cover the area with surgical pack

The periodontal flap

Why do we do periodontal flap surgery?

- To provide access and direct visibility to the root surface for thorough debridement as in some non-surgical situations, the complete removal of subgingival plaque and calculus is not possible
- To eliminate the pathological changes in the pocket wall
- To gain access for osseous resective surgery
- In case of furcation involvement of grade 2 or 3 to ensure complete removal of irritants and perform any necessary root resection and hemisection
- To create a stable easy maintainable state
- To promote periodontal regeneration by applying certain materials
- The successful periodontal therapy is based on the total elimination of plaque, calculus and diseased cementum from root surface
- Whenever there is a pocket, plaque control becomes difficult and the deeper the pocket the more difficult is the access

Advantages of flap operation

- 1- Preservation of existing gingiva
- 2- The root surfaces, marginal alveolar bone and furcation areas are exposed
- 3- The flap can be returned to its origin position or displaced apically, coronally or laterally
- 4- The post operative period usually shows less discomfort to the patient compared to gingivectomy

Classification of flaps

Based on bone exposure after flap reflection

- **Full thickness flap:** includes epithelium, connective tissue and periosteum elevated from underlying bone
- **Partial thickness flap (split flap):** includes epithelium and CT reflected from bone and periosteum

Based on placement after surgery

- Non displaced flaps
- Displaced flaps

Based on the management of the papilla

- Conventional flap
- Papilla preservation flap

The flap techniques for pocket therapy

- 1- The original WIDMAN (1918) by Leonard Widman
- 2- The Neuman flap (1920)
- 3- The modified flap operation (the Kirkland flap) 1931
- 4- The apically repositioned flap (1962) by Friedman
- 5- The modified Widman flap (1974) by ramfjord and Nissle
- 6- The papilla preservation flap (1985) by Takei et al

References

- Clinical Periodontology and Implant Dentistry By Jan Lindhe
- Colour Atlas of Dental Medicine and Periodontology

The original WIDMAN flap

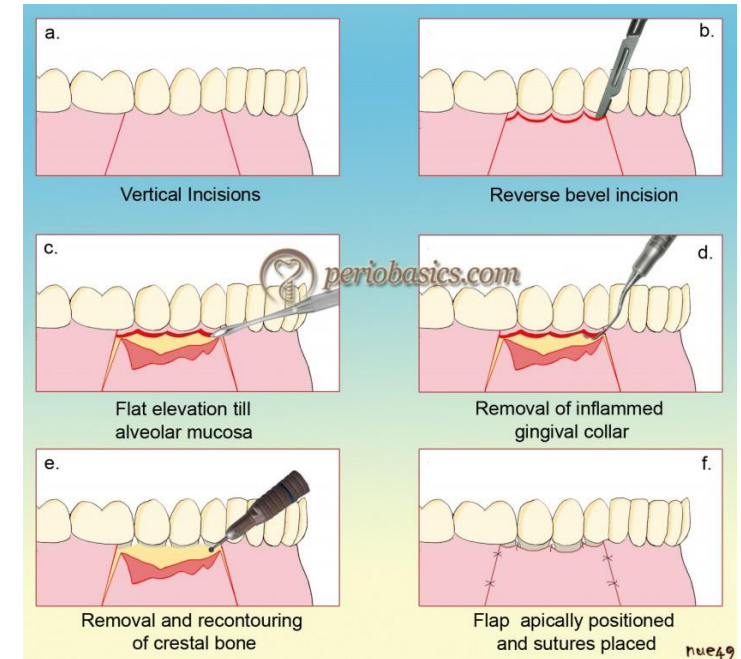
- One of the first detailed description of use flap procedure for pocket elimination was published in 1918 by Leon Widman

Aim

- To remove the pocket epithelium and inflamed connective tissue thereby enabling for optimal cleaning of root surface

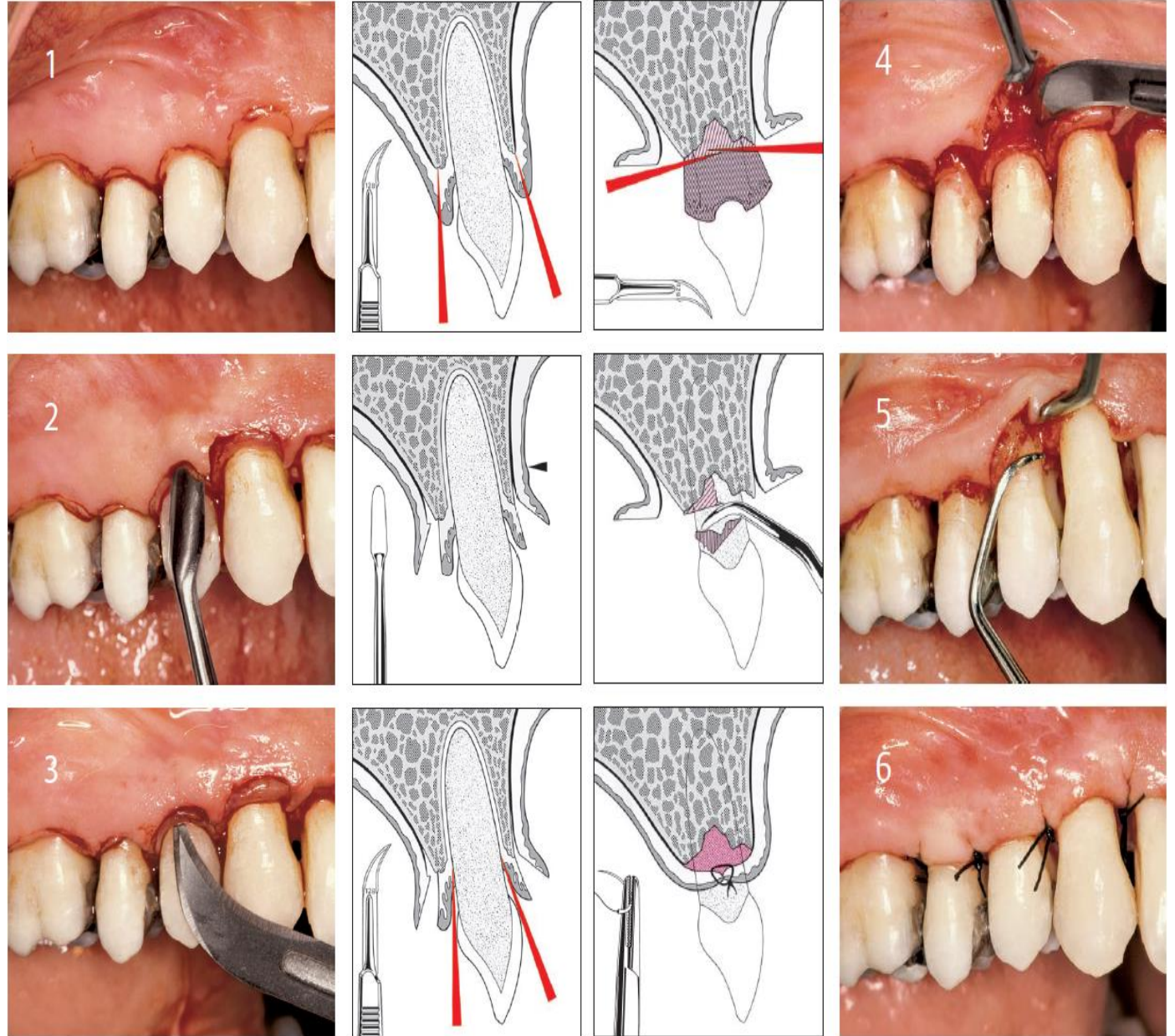
The modified Widman flap

- In 1974 Ramford and Nissle described the modified Widman flap procedure
- It is also known as replaced flap
- It is different from Widman flap in the manner that no apical displacement of flap takes place and no osseous recontouring is to be done



Technique

- 1- Intra-crevicular incision is made through the base of the pockets on both labial and lingual aspects of the teeth
- 2- The gingiva is reflected labially and lingually to expose the diseased root surfaces which are debrided carefully
- 3- Angular bony defects are curetted
- 4- The pocket epithelium and granulation tissue are removed from the inner surface of the flap
- 5- The flap is reflected to its original position and sutured with interproximal sutures



Advantages

- 1- No extensive sacrifice of non-inflamed tissues and no apical displacement of the flap, thus its useful in anterior regions for aesthetic reasons
- 2- Potential for regeneration in case of infrabony defects

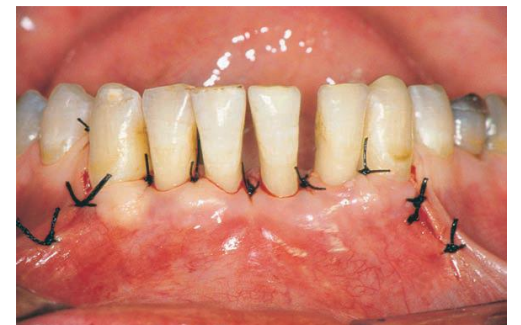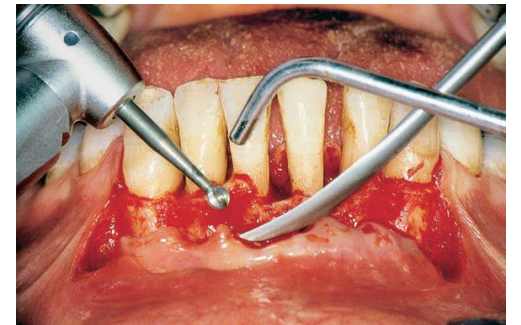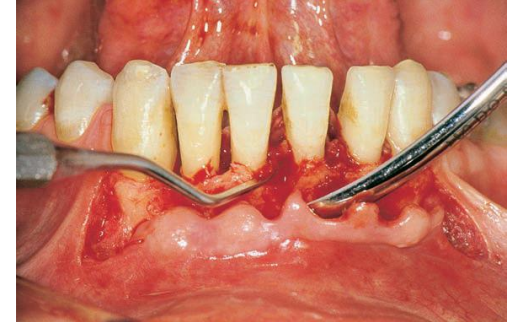
The apically repositioned flap

Advantages

- 1- Provides accessibility and eliminates the pocket
- 2- Preserves or increases the width of the attached gingiva by transforming the previously unattached keratinised pocket wall into attached tissue

Disadvantages

- Root exposure may cause aesthetic problems hypersensitivity and increased risk of root caries

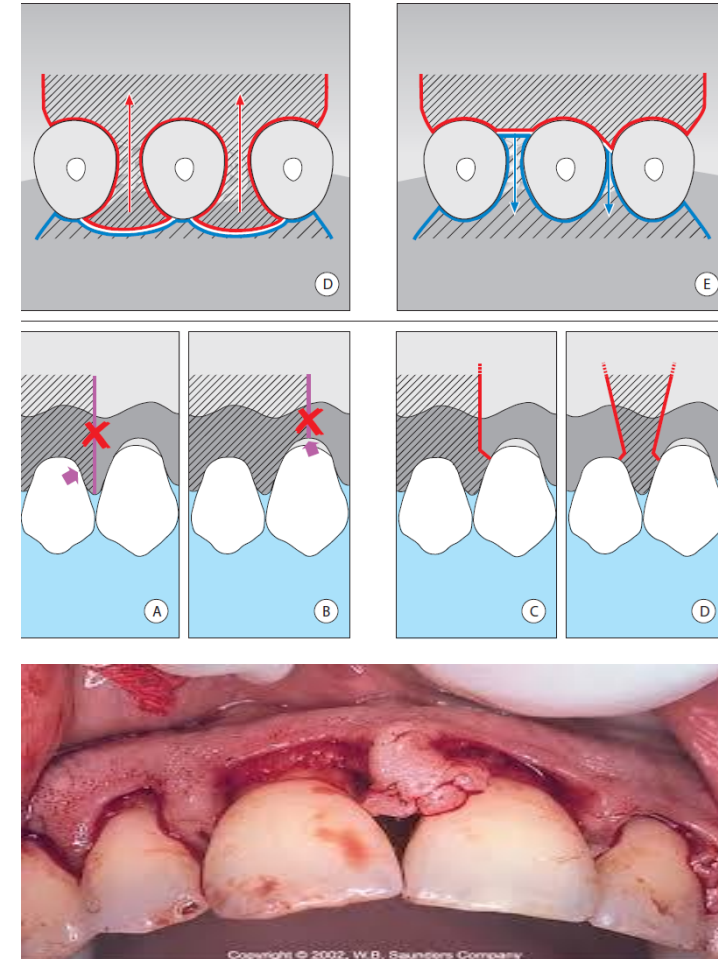


Contraindications

- 1- Periodontal pockets in aesthetic areas
- 2- Deep infrabony defects
- 3- Patients at high risk for caries
- 4- Severe hypersensitivity
- 5- Teeth with severe attachment loss and unfavourable clinical crown\root ratio

Papilla preservation flap

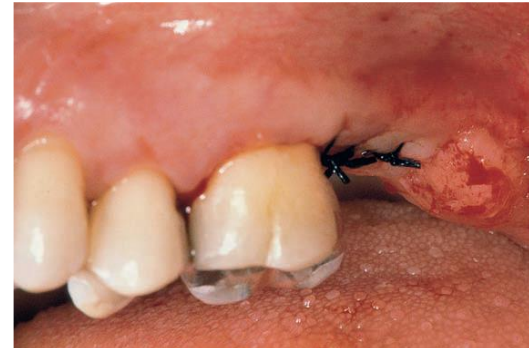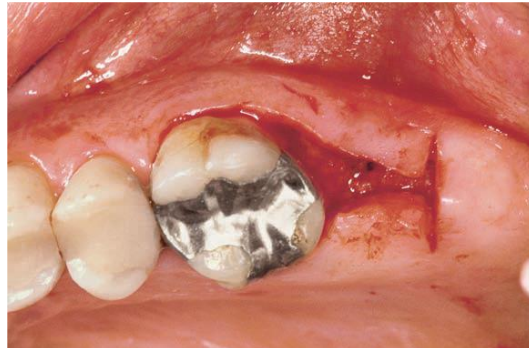
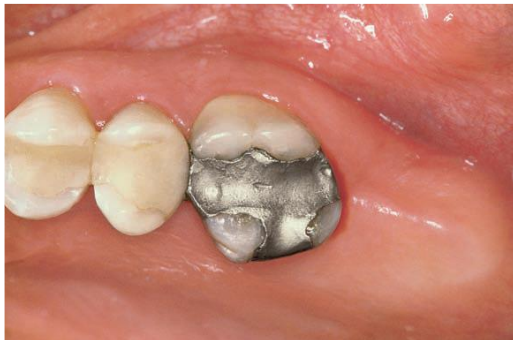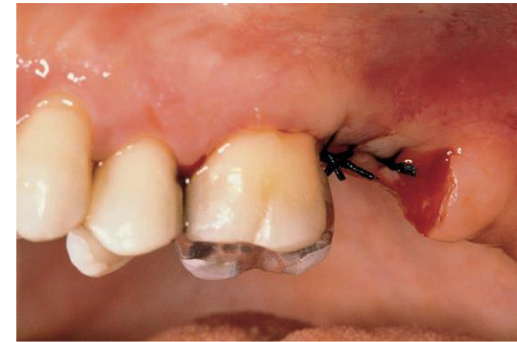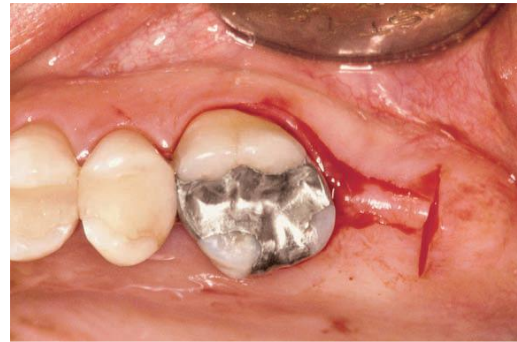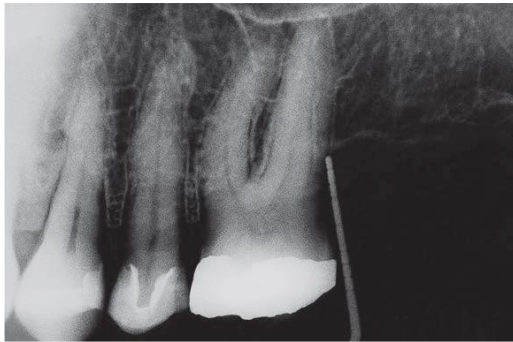
- It is to be done to preserve the interdental soft tissue for maximum soft tissue coverage following surgery in the interdental region
- For aesthetic purpose in maxillary anterior region
- There must be adequate interdental space to allow the intact papilla to be reflected with the facial or lingual\palatal flap
- In case narrow interdental space, which making it impossible to perform a papilla preservation flap, a conventional flap with only crevicular incisions will be made



Distal wedge flap

The incision start on the distal surface of the tuberosity and carried forward to the base of the pocket on the distal surface of molar

However, when only limited amounts of keratinised gingiva present or if a distal angular bony defect has been diagnosed, the distal wedge procedure facilitates access to the osseous defect, preserve sufficient amount of keratinised tissue and produces a primary closure wound



Respective osseous surgery

Procedures designed to restore the form of pre-existing alveolar bone to a level present at the time of surgery, or slightly more apical to this level

Osteoplasty: refers to reshaping the bone without removing the supporting bone

Ostectomy or osteotomy: includes the removal of tooth surface alveolar bone

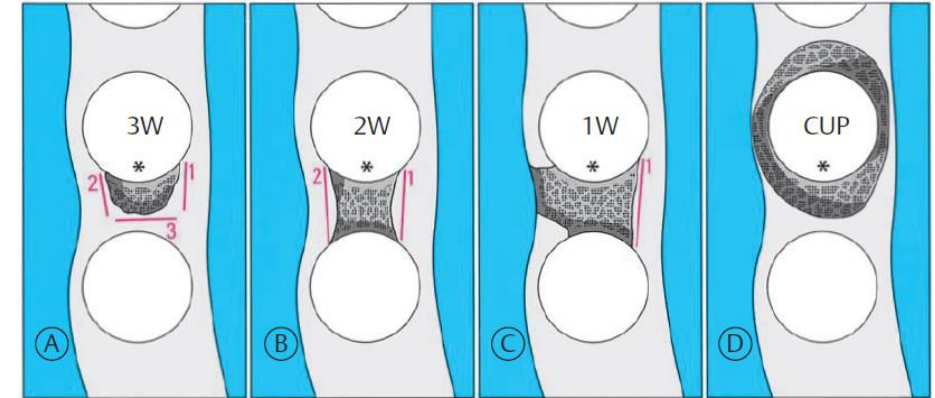
- One or both of these procedures may be necessary to produce the desired result

Indications

- 1- Ostectomy is the best to be applied to patients with early to moderate bone loss (2-3 mm) with moderate root trunk length that have bony defects with one or two walls
- 2- To facilitate certain restorative and prosthetic dental procedures
- 3- Furcation involvement
- 4- Excessive bony ledges and exostosis
- 5- Provide a means of producing optimal crown length for cosmetic purposes

Selection of treatment technique

- **One-wall angular defects** usually need to be recontoured surgically
- **Three-wall defects**, particularly if they are narrow and deep, can be successfully treated with periodontal regenerative procedures
- **Two-wall angular defects** can be treated with either method, depending on their depth, width and general configuration



Periodontal plastic and aesthetic surgery

Objectives

- 1- Problems associated with attached gingiva
- 2- Problems associated with a shallow vestibule
- 3- Problems associated with aberrant frenum
- 4- Aesthetic surgical therapy
- 5- Tissue engineering

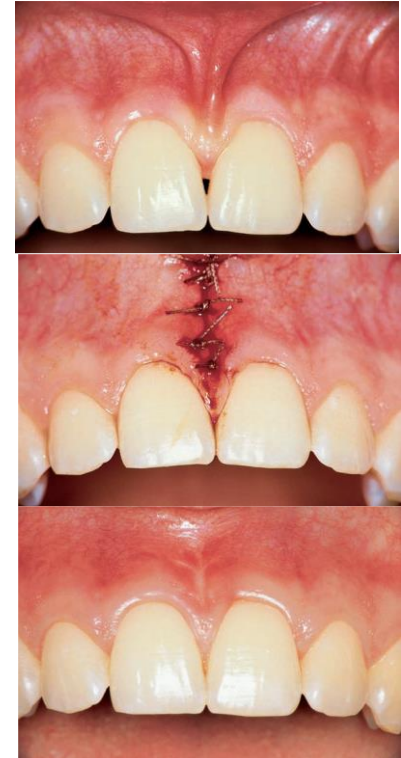
Frenectomy and frenotomy

Frenectomy is a complete removal of the frenum, including its attachment to the underlying bone, this may be required in the correction of an abnormal diastema between the maxillary central incisors

Frenotomy is the relocation of the frenum, usually in a more apical position

Suturing

- The needle is held with the needle holder, and should enter the tissues at right angles and should be no less than 2mm from the incision. The knot should not be placed over the incision
- The use of non irritant, non absorbable, non filamentous material is recommended
- The expanded polytetrafluoroethylene, synthetic, monofilament suture is an excellent non absorbable suture is widely used nowadays
- The dimensions which are usually preferred are 4\0, 5\0. while the finer suture materials are 6\0, 7\0 which may be used particularly with periodontal micro and plastic surgery
- Sutures are usually removed after 7-14 days



Suturing technique

1- Interrupted interdental suture

Provides close adaptation between buccal and lingual flaps with equal tension on both units when buccal and lingual flaps elevated and repositioned at the same level

2- Figure- eight suture

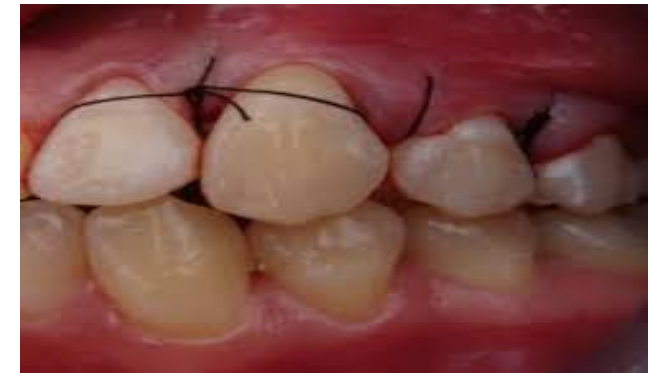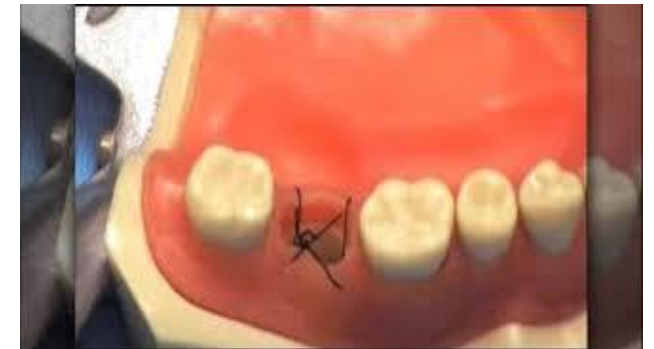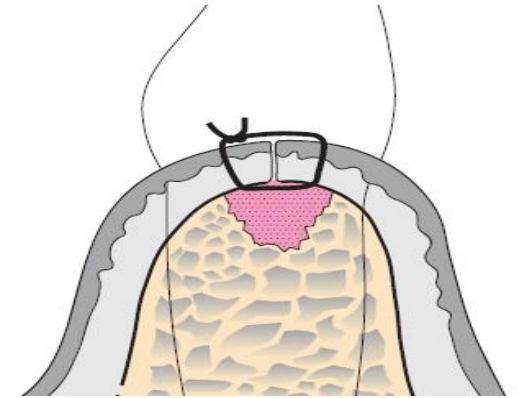
Used to approximate the buccal and lingual flaps when flaps are not in close apposition as a result of **apical flap position** or **non scalloped** incisions. This is similar to perform the direct ligation

3- Suspensory suture (independent sling suture)

Is used when flap elevated on one aspect of buccal or lingual or when buccal and lingual flaps are to be repositioned at different levels

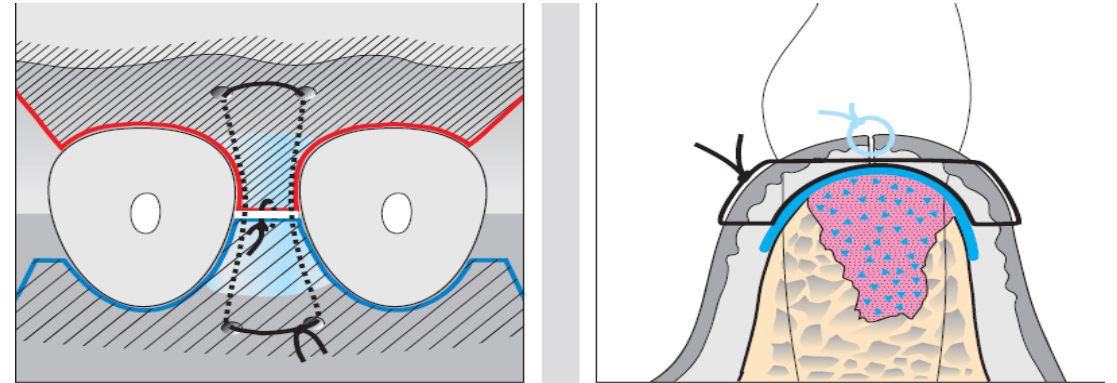
4- The continuous independent sling suture

Is used in surgical procedures involving several teeth when buccal and lingual sides are to be repositioned apically



5- Modified mattress suture

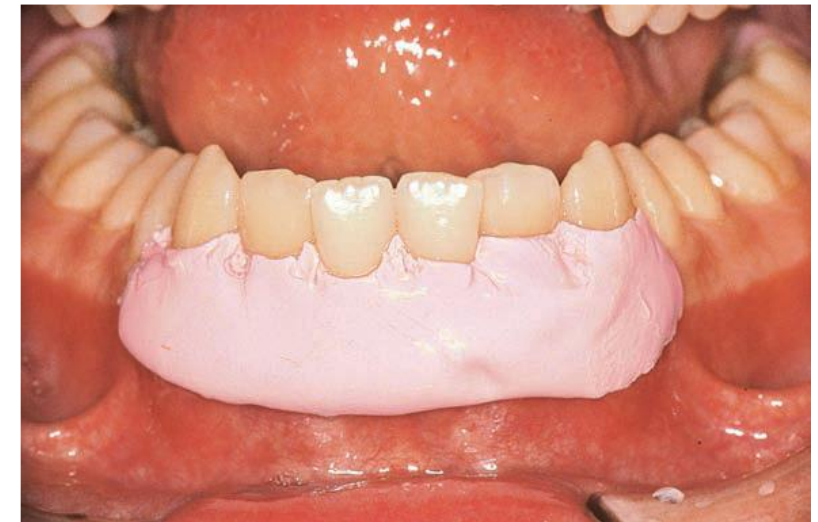Required for coronal advancement of the flap



Periodontal dressing

Purpose of periodontal dressings

- 1- Protects the wound post-surgically
- 2- Maintains close adaptation of the flap to the underlying bone
- 3- Helps in prevention of bleeding
- 4- Prevents the formation of excessive granulation tissue
- 5- Protects the newly exposed root surfaces from environmental temperature changes
- 6- Facilitates oral hygiene maintenance
- 7- Facilitates masticatory process
- 8- Helps in prevention of infection
- 9- Aids in patient comfort



Properties

- 1- Soft and flexible to facilitate its placement and adaptation
- 2- Hardens within a reasonable time
- 3- Sufficiently rigid to prevent fracture and dislocation
- 4- Smooth surface after setting to prevent irritation to the cheeks and lips
- 5- Bactericidal properties to prevent plaque formation
- 6- Does not interfere with healing

Types of periodontal dressings

1- Zinc oxide eugenol dressings

- Based on the reaction of zinc oxide and eugenol
- Supplied as liquid and powder that mixed before use
- Eugenol in this type of pack may induce an allergic reaction

2- Zinc oxide non eugenol dressings

- Supplied in two tubes, which can be mixed before use until a uniform colour is obtained
- One tube contains zinc oxide, oil for plasticity and lorcithidol as a fungicide
- The other tube contains liquid coconut fatty acids that have been thickened with a bacteriostatic agent

3- Cyanoacrylates

4- Tissue conditioners

5- Dressings which contain antimicrobial agents such as tetracycline

Non eugenol dressings

Such as **Coe-pack**, peripack, vocopack, perio-care, perioputty, collagen dressings, barricade...etc



Post operative instructions

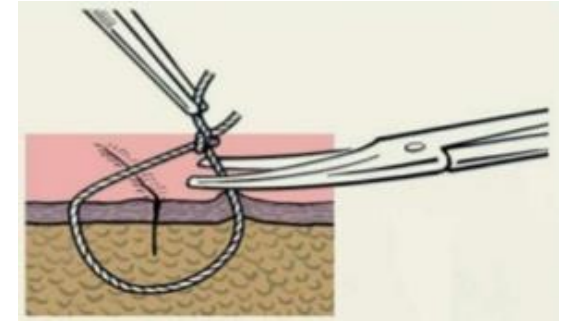
- Should take the prescribed medications regularly
- The pack should remain in place for at least one week or until get removed by the dentist at the next visit
- Avoiding hot food after the first three hours after the operation to permit the pack to harden
- Avoiding citrus fruits or juices, highly spiced foods and alcoholic beverages
- Avoiding smoking which will irritate the gum and delay healing
- Avoiding brushing over the pack (but brush the other areas)
- Rinsing with 0.12% chlorhexidine immediately after the surgical procedure and twice daily
- Ice application is recommended intermittently on the face over the operated area
- Swelling may be seen 1 to 2 days after the surgery and subsides in 3 to 4 days

First post operative week

- Properly performed periodontal surgery presents no serious post operative problems, however the following complications may arise in the first post operative week
- Persistent bleeding after surgery, the pack should removed and check for bleeding points which should be stopped with pressure, electrosurgery or cautery
- Sensitivity to percussion, extension of inflammation into periodontal ligament may cause sensitivity to percussion, relieving the occlusion is usually helpful
- Swelling which is usually subsides by the the 4th day
- Feeling of weakness, usually due to transient bacteraemia induced by the procedure. The reaction is prevented by medication such as amoxicillin 500mg for 5 days

Removal of the pack

When the patient returns after one week, the periodontal pack should be removed and the area should be rinsed with normal saline or antiseptic solution



Mouth care between procedures

- Vigorous brushing is not feasible during the first week after the pack is removed
- The patient is advised to use soft brush and light water irrigation in addition to chlorhexidine mouth wash
- Post operative dose of ibuprofen 400-600mg followed by one tablet every 8 hours

References

- Clinical Periodontology and Implant Dentistry By Jan Lindhe
- Colour Atlas of Dental Medicine and Periodontology

New attachment and guided tissue regeneration (GTR)

Aspects of periodontal healing

- 1- Regeneration
- 2- Repair
- 3- New attachment

1- Regeneration: is the growth and differentiation of new stem cells and intercellular substances to form new tissues. It occurs by growth from the type of tissue that has been destroyed or from its precursor

In the periodontium:

- 1- Gingival epithelium is replaced by epithelium
- 2- Connective tissue, PDL, bone and cementum all are derived from connective tissue, undifferentiated CT cells (stem cells) which develop into fibroblasts, osteoblasts and cementoblasts

Regeneration under normal conditions

Regeneration of the periodontium is a continuous physiologic process, new cells and tissues are continuously being formed to replace mature and dead cells, this is termed '**wear and tear repair**'

Regeneration during destructive periodontal disease

Most gingival and periodontal diseases are chronic inflammatory conditions, regeneration is a part of healing processes. However, bacteria and its products are injurious to the regenerating cells and tissues

- But removing dental plaque can prevent further complications and regenerative capacity will establish

2- Repair : restoration of the continuity of a diseased marginal gingiva and reestablishment of a normal gingival sulcus at the same level as the base of a pre-existing pocket, called (healing by scar)

- Bone loss is arrested with mobilisation of epithelial and CT cells into the damaged area with increase mitotic division to provide a sufficient number of cells

3- New attachment: refers to repair areas of the root which is not previously exposed to the pockets, but after surgical detachment of the tissues or after traumatic tears in cementum, tooth fractures or treatment of periapical lesion

Epithelial adaptation: close apposition of the gingival epithelium to the tooth surface without complete obliteration of the pocket, may be as resistant to disease as true connective tissue attachments

- 4-5mm pocket depth with absence of bleeding on probing post therapy may be acceptable. This may indicate that the **deep sulcus** persists in an inactive state

Regeneration of PDL is the basis for new attachment because:

- 1- PDL provides continuity between the alveolar bone and cementum
- 2- PDL contains cells that can synthesize and remodel the 3 connective tissues of the periodontium

The possible outcome of therapy

During healing stages of a periodontal pocket, the area is invaded by cells from 4 different sources which modified the final outcome of pocket healing

1- Oral epithelium: if the epithelium proliferates along the tooth surface before the other tissues and reach the area, the result will be a long junctional epithelium

2- Gingival connective tissue: if the cells from gingival CT are the first to populate in the area, the result will be fibres parallel to the tooth surface and remodelling of the alveolar bone, with no attachment to the cementum (recurrent pocket is possible)

3- Bone: if bone cells arrive first, root resorption and ankylosis may occur

4- Periodontal ligament: when cells from PDL proliferate coronally, there is a new formation of cementum and PDL (new attachment)

- This is the ideal outcome of periodontal therapy as it will obliterate the pocket and reconstitute the marginal periodontium

Evaluation of new attachment and bone regeneration

1) Clinical methods: comparison of pre and post treatment records of

- a. Pocket probing
- b. Attachment level
- c. Gingival indices
- d. Bone level

A- Pocket probing: the distance from gingival margin to the apical extent of periodontal probe (the depth of penetration of a probe in a pocket)

- That may depend on factors such as the size of the probe, the force which is introduced, the direction of penetration, the resistance of the tissues and convexity of the crown
- Reduction of this penetration after treatment may be a result of reduced inflammatory response rather than gain new attachment

B-Attachment level: is the distance between the base of the pocket and a fixed point on the crown, such as the cemento-enamel junction which is measured by periodontal probe

- It is more important than probing pocket depth, because the latter may change due to displacement of the gingival margin and degree of inflammation

C- Gingival indices

The gingival index of Loe and Silness (1963) and the sulcus bleeding index of Muhlemann and Son (1971) are the most useful in clinical evaluation of gingival health before and after treatment

D-Alveolar bone level

Is evaluated clinically by (trans-gingival probing) after anaesthetizing the area

- It determines the height and contour of the facial and lingual bones obscured on the radiograph by the dense roots
- The architecture of the interdental bone also can be evaluated

2- Radiographic methods

- Standardised technique is needed for reproducible positioning of the film and the tube, even though, this technique is less reliable than clinical probing technique, because a sufficient loss should take place at the alveolar crest to be recognised radiographically (not sensitive)

3- Surgical re-entry

- Evaluation can be performed by taking repeated impression. This can give a good view of the state of the bone crest that can be compared with the view taken during the initial surgical intervention

This method has 2 disadvantages:

- a. Requires unnecessary second operation
- b. Does not show the type of attachment if it is new attachment or long junctional epithelium

4- Histological methods

- Type of attachment can be determined only by histologic analysis of tissue blocks obtained from the healed area
- Animal studies can be used because this method needs extraction of the examined tooth with its periodontium after successful treatment, therefore it is not used in human

Reconstructive surgical techniques

Can be divided into two major approaches

- 1- Non-bone graft associated new attachment
- 2- Bone graft associated new attachment or combination of both approaches

1- Non-bone graft associated with new attachment

New attachment is more likely to occur when the destructive process has occurred very rapidly e. g after treatment of pockets with acute periodontal abscess and acute necrotising ulcerative gingivitis (ANUG)

a. Removal of junctional and pocket epithelium: they considered as a barrier to successful therapy because its presence would interfere with the apposition of connective tissue and cementum
- Several methods have been recommended to remove the junctional and pocket epithelium, including curettage, chemical agents, ultrasonic, laser and surgical technique

b. Preventing or impeding the epithelial migration as in coronally displaced flap

c. Clot stabilisation, wound protection and space creation

Preservation of the root surface fibrin clot interface prevents apical migration of the gingival epithelium and allows for connective tissue attachment during the early wound healing

d. Laser-assisted new attachment procedure

The role of laser in periodontal therapy remains controversial. However, the use of neodymium, yttriumaluminum garnet (Nd-YAG) to perform surgical procedure has been reported for the management of chronic periodontitis and can potentially result in a new attachment and regeneration

e. Guided tissue regeneration (GTR)

Is used for prevention of epithelial migration along the cemental wall of the pocket and maintaining space for clot stabilisation

- The procedure can be done by placing barriers of different membranes to cover the bone and periodontal ligament and temporarily separating them from the gingival epithelium and connective tissue.
- In this way it favours repopulation of the area by cells from periodontal ligaments and alveolar bone

Guided periodontal regeneration

- Generation 1= GTR (guided tissue regenerative membrane)
- Generation 2 = Biomaterials such as EMD (enamel matrix derivative protein), BMP (bone morphogenic protein) and PRP (plasma rich protein), PRF (plasma rich fibrin)
- Generation 3 = growth factors, stem cells and tissue engineering

Regenerative procedures

Periodontal regenerative procedures used to improve:

- 1- Local gingival architecture
- 2- Function
- 3- Prognosis

- The infra-bony defect could be classified according to the number of surrounding bone walls into:
 - **a.** one wall defect
 - **b.** Two wall defect
 - **c.** Three wall defect

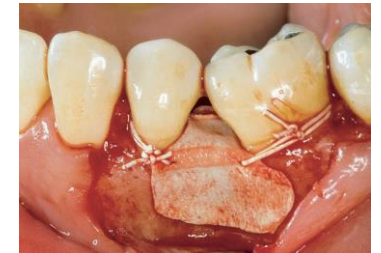GTR disadvantages

Non-absorbable

- a. Second surgery required after initial stage of healing 3-6 weeks
- b. Exposure to oral environment
- c. Bacterial contamination
- d. Failure or collapse

Absorbable

- a. Risk of exposure
- b. Collapse into the defect area
- c. Technical difficulties
- d. Harmful degradation products of synthetic membranes
 - **Preparation of the root surface:** changes of in the root surface of periodontal pockets that interfere with a new attachment are degeneration of remnants of sharpey's fibers, accumulation of bacteria and their product and disintegration of the cementum and dentin
 - These can be eliminated by thorough root planning with several substances which can give better conditioning of root surface for new attachment of CT such as 1. Citric acid 2. Fibronectin 3. Tetracycline



2. Bone graft associated with new attachment

Grafting procedure to stimulate periodontal regeneration, the flap approach was combined with the placement of bone graft or implant materials into the curetted bony defect

- These materials may actively induce bone formation or through its own viability may deposit new bone
- The various graft and implant materials used can be placed into four categories depend on their sources

- I. **Autogenous graft:** grafts transferred from one position to another within the same individual and harvested either from intra or extra oral (iliac) donor site. It comprises:
 - a. Cortical bone
 - b. Cancellous bone marrow, from maxillary tuberosity, edentulous areas and healing bone
 - c. Bone blend which is combination of the previous two.

Bone is removed from predetermined sites, triturated in a capsule to be workable ,plastic like mass and packed into bony graft

- II. **Allograft:** a graft transferred between genetically dissimilar members of the same species (cadaver)
 - a. Viable cancellous bone and bone marrow
 - b. Sterilised cancellous bone and bone marrow
 - c. Freeze-dried bone (FDBA)

- Decalcification dried bone allograft is preferred, because it has a higher osteogenic potential than freeze-dried bone graft, because the process of demineralisation followed by acid application can expose the component of bone matrix which are closely associated with collagen fibrils as bone morphogenic protein (BMP)

III. Hetro or xenografts : grafts are taken from a donor of another species (calf or ox bone)

- Bio-oss is the most widely used, it is an inorganic bovine derived bone
- In periodontology, bio-oss used as graft material covered by absorbable membrane

IV. Alloplastic materials (non-bone graft synthetic material): inert implant calcium phosphate biomaterials, which have been used as substitutes for bone graft such as:

- a. Hydroxyapatite:** similar to that found in bone, it is non bio-absorbable
- b. Tricalcium phosphate:** is partially bio-absorbable

Other alloplastic materials other than calcium phosphate are sclera, cartilage, plaster of Paris and bioactive glass

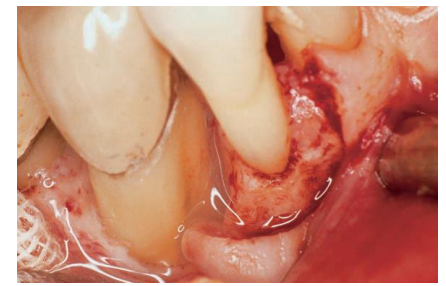
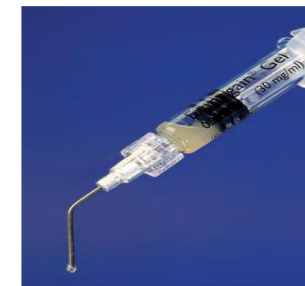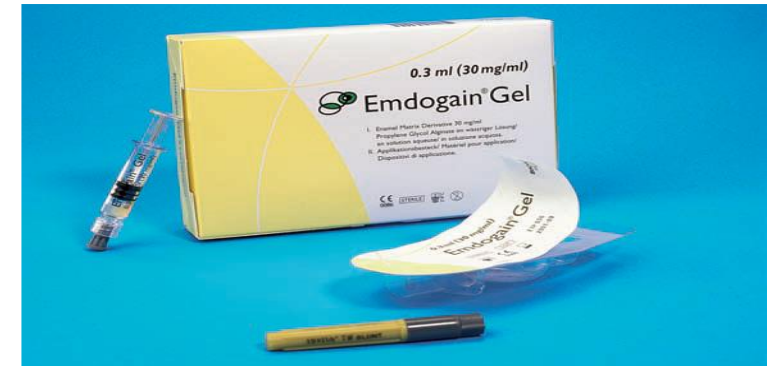The grafting materials for treatment of periodontal disease may either:

- Contains bone forming cells to do osteogenesis such as in autograft
- Serves as scaffold for bone formation (osteo-conduction), such as Bio-oss and alloplastic materials
- This material induce bone formation when placed next to viable bone but not when surrounded by non-bone forming tissue such as skin
- Inducing bone formation (osteo-induction) because the matrix of bone graft contains bone inducing substances (osteogenic markers)

Generation 2 (Bio active materials)

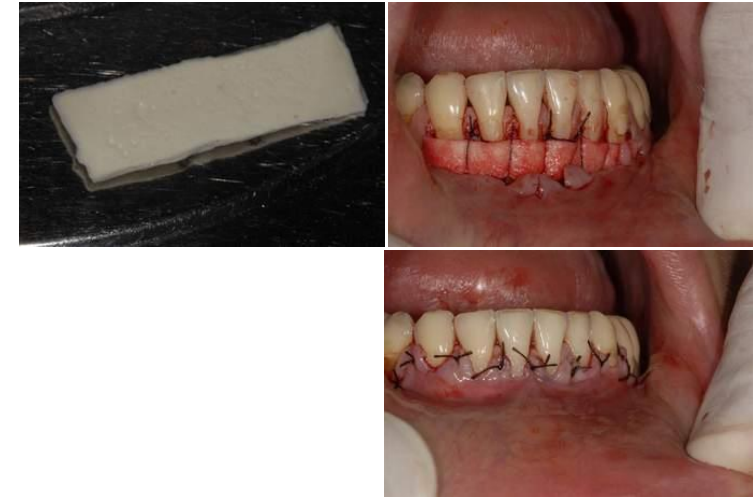Enamel matrix derivatives: Emdogain, enamel matrix protein mainly derived (Amelogenin) are secreted by Hertwigs epithelial root sheath during tooth development and induce acellular cementum formation

- These proteins are believed to favour periodontal regeneration
- The available derivative obtained from porcine teeth name (emdogain), which is available as gel consisted of 90% amelogenin and the rest are primarily proline-rich non amelogenin, tuftelin, etc.



Acellular dermal matrix allograft (ADMA) (Alloderm): acellular human cadaver skin is a relatively new type of bioabsorbable grafting material that has been obtained from tissue skin

- It is immunologically inert as the most target of rejection have been removed during initial epithelisation and decellularization processes
- In periodontal surgery, the use of ADMA is recommended in the management of ridge deformities, also in increasing keratinised tissue around teeth and dental implants and for root coverage



Generation 3 (growth regulatory factors for periodontal regeneration)

Growth factor is a general term to denote a class of polypeptide hormones that stimulate a wide variety of cellular events, such as proliferation, chemotaxis, differentiation and production of extracellular matrix protein

- Proliferation and migration of periodontal ligament cells and synthesis of extracellular matrix as well as differentiation of stem cells into osteoblasts and cementoblasts is a prerequisite for obtaining periodontal regeneration
- The effect of various growth factors were studied in vitro and a significant regeneration potential of growth factors was also demonstrated in animal models
- These growth factors are primarily secreted by macrophages, endothelial cells, fibroblast and platelets

The important growth factors are:

- Platelets derived growth factors (PDGF)
- Insulin-like growth factor (IGF)
- Bone morphogenic proteins (BMPs)
- Transforming growth factor (TGF)

Ideal requirement of bio-materials

- Biocompatibility
- Enhancement of clinical attachment level
- Reduction of probing depth
- Hard tissue fill of the intrabody defects

Factors influencing the success or failure of all regeneration techniques

- Plaque control
- Systemic status that affect the periodontium
- Traumatic injury to teeth or tissues
- Root preparation
- Wound closure
- Soft tissue approximation
- Post operative and long term maintenance

References

- Clinical Periodontology and Implant Dentistry By Jan Lindhe
- Colour Atlas of Dental Medicine and Periodontology

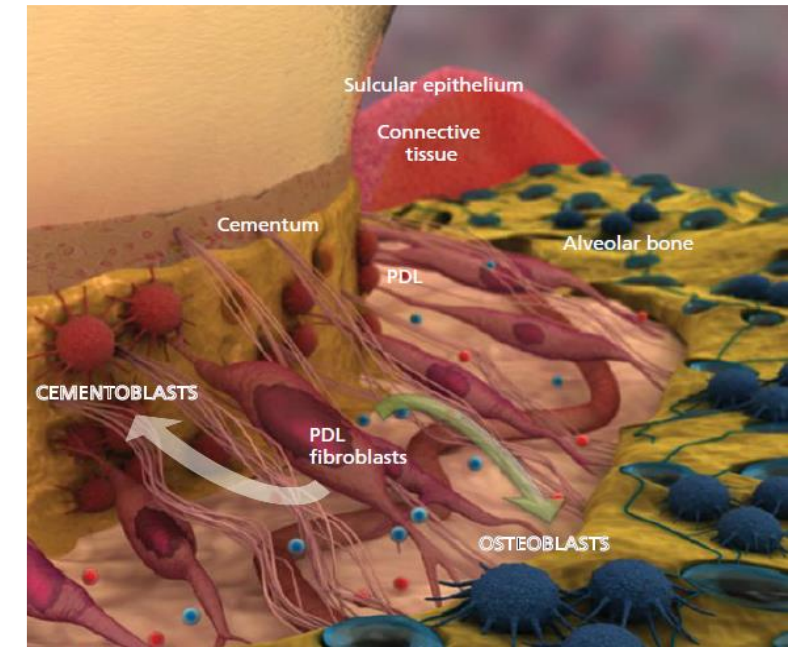
Phases of wound healing

- The wound healing process is a dynamic one which can be divided into three phases, whether wounds are closed by **primary intention** or left to heal by **secondary intention**
- The process is not a linear and often wounds can process both forwards and back through the phases depending upon intrinsic and extrinsic factors
- The phases of wound healing are:

1- Inflammatory phase

2- Proliferation phase

3- Maturation phase



The **inflammatory phase** is the body's natural response to injury. After initial wounding, the blood vessels in the wound bed contract and a clot is formed

- Once haemostasis has been achieved, blood vessels then dilate to allow essential cells, antibodies, white blood cells, growth factors, enzymes and nutrients to reach the wounded area
- This leads to a rise in exudate levels and at this stage the **characteristic signs of inflammation** can be seen; erythema, heat, oedema, pain and functional disturbance
- The predominant cells at here are phagocytic cells (neutrophils and macrophages), mounting a host response and autolysing any devitalised necrotic/sloughy tissue

During **proliferation**, the wound is rebuilt with a new granulation tissue which is comprised of **collagen** and **extracellular matrix** and into which a new network of blood vessels develop, a process known as angiogenesis

- Healthy granulation tissue depends upon the fibroblast receiving sufficient levels of oxygen and nutrients supplied by the blood vessels
- Healthy granulation tissue is granular and uneven in texture, it does not bleed easily and is pink/red in colour
- The colour and condition of the granulation tissue is often an indicator of how the wound is healed
- Dark granulation tissue can be indicative of poor perfusion, ischemia and/or infection
- Epithelial cells finally resurface the wound, a process known as **epithelisation**

Maturation is the final phase occurs once the wound has closed

- This phase involves remodeling of collagen from type III to type I
- Cellular activity reduces and the number of blood vessels in the wounded area regress and decrease

Repair of wounds: include 2 responses

1- Epithelial response which means that mobilisation and migration of epithelial cells to the wound margin

2- Connective tissue response

- Haemostasis
- Inflammation
- Proliferation
- Synthesis (collagen synthesis)

Initial response to wounding:

A. Haemostasis

- Haemorrhaging results in deposition, aggregation of **platelets** and coagulation to form a clot within minutes of wounding. The clot aids in

- 1- Serving as haemostatic barrier
- 2- Unite the wound margin
- 3- Providing a scaffold for subsequent migration of reparative cells

B. Inflammatory cell activation, migration and function. These inflammatory cells derived from 3 sources

- 1- Cells normally present in the tissue
- 2- Cells extravasated when blood vessels are damaged
- 3- Cells carried in intact blood vessels

The most important inflammatory cells are:

- **Neutrophil** within few hours of injury to reach maximum concentration at 24 hours. The main functions are: **phagocytosis** and **mediated inflammatory changes**

C. Proliferation of fibroblast (2 days and on) from undifferentiated perivascular cells (stem cells)

D. Collagen synthesis by fibroblasts

Wound union

A. Primary union: if wounds are surgically produced in surgically sterile environments and their edges are brought closely together, it can be said that **primary union** or **healing by primary intention** has been achieved and under these condition there is:

- 1- Minimal trauma
- 2- Little chance of secondary infection
- 3- Healing quickly without complications

Steps of healing

- 1- Clot formation
- 2- Inflammation
- 3- Granulation tissue formation
- 4- Epithelisation
- 5- Cicatrisation (scar formation)

B. Secondary union: it takes place when the edge of wound can't be brought together e.g. gun shot exit wounds, free gingival graft, the wound produced at the donor site can't be sutured and is left open, it termed secondary union or healing by **secondary intention** or **granulating-in**

Steps of healing are the same as the primary healing

Wound healing after periodontal treatment

Rationale for periodontal treatment

1. Eliminate pain, gingival inflammation and bleeding
2. Reduce periodontal pockets
3. Eliminate infection and stop pus formation
4. Arrest soft tissue and bone destruction and restore the tissue which is destroyed by the disease
5. Reduce abnormal tooth mobility and establish optimal occlusal function
6. Re-establish the physiologic gingival contour necessary for the preservation of periodontal health
7. Prevent recurrence of the disease and so reduce tooth loss

Healing after scaling and blind root planning

- If scaling is done with overlapping strokes, it is technically possible to detach all the subgingival deposits
- Immediately after conclusion of a successful subgingival scaling, all dental plaque organisms are detached from the tooth, many of the bacteria are swimming in the exudates
- However, the bleeding follows that will carry most of detached particles, including bacteria out of the pocket during and immediately after the debridement
- The bleeding will stop in a few minutes, but a fairly profuse exudate from damaged blood vessels will continue for many hours
- The exudate (a mixture of water, serum proteins and white blood cells) will accumulate between the tooth and the soft tissue and is called gingival crevicular fluid (GCF)

- **GCF** secretion per a day of normally healthy gingiva is 0.5-2.5 mL/day. It also contributes to the mechanical cleansing of pocket because it seeps out in a continuous flow
 - Most of the detached plaque organisms are brought out of the pocket with the gingival fluid in few minutes
 - Those organisms which may have been captured in the soft tissue are being eradicate by PMNL.
 - Finally large numbers of bacteria enter the lymph and blood vessels to brought to the regional lymph nodes or to spleen where they are destroyed
-
- Only a few hours after debridement, all the bacteria are removed (mostly by means of GCF)
 - The secretion of gingival fluid will then subside and epithelium begins to proliferate
 - The granulation tissue in the lateral wall of the pocket, in an environment free of plaque and calculus will be changed into connective tissue; thereby minimising shrinkage, this is regarded as an important advantage of blind root planning over radical surgery, i.e.; less trauma and haemorrhage will result in less gingival shrinkage during healing
 - This is very important for aesthetic which is a major consideration of therapy, particularly in the anterior region
 - Furthermore, exposed cementum to a pathological pocket is cytotoxic to both epithelium and fibroblast by bacteria with their toxins penetrating this cementum

- Removal of exposed cementum eliminates undesirable surface contamination and provides a healthy surface to which fibroblasts adhere
- Thus, reduction of pocket probing depth following blind root planning is partly due to shrinkage of gingival wall of the pockets (repair), forming long junctional epithelium in most of the cases and partly from regeneration of lost attachment

Healing following surgical procedure

Gingivectomy: healing will be by secondary intention (secondary union) which occurs by the formation of granulation tissue which grows from the base of the wound to fill the defect

- The vascular and fibroblastic proliferation together make up the granulation tissue much more abundant and healing taken much larger than when it occurs by first intention
- The main problem after gingivectomy is for the epithelial cells to cover the open wound
- The epithelial cells are the main actors in the healing of the gingivectomy

Steps of healing

1- The incision exposes many blood vessels of all sizes, when the pack is applied, blood clot is formed and blood vessels are sealed with fibrin to stop further bleeding. The underlying tissue becomes acutely inflamed with some necrosis

2- The blood clot below the pack contains large numbers of microorganisms. However, in most cases they are quickly phagocytosed by PMNLs which are migrating into the area in large numbers

- Therefore, the blood clot is likely to be free of bacteria within hours

3- The next step in the healing is **the proliferation of macrophages** which engulf the RBC and disintegrating PMNLs

- Within 1-2 days, epithelial cells start to migrate from oral mucosa
- These cells migrate on a network of fibrin
- Surface epithelisation is completed after 5-14 days

4- Under particularly favourable condition, epithelial cells can migrate as far as 2mm in 24 hours. After gingivectomy, the speed must considerably be less and it may take 1-2 weeks before the oral epithelial cells reach the tooth surface

5- If the regeneration occurred in a plaque free tooth surface, free gingival unit will form. This regeneration occurs in coronal direction and appear clinically as a gain in marginal height zero '**pocket**'

6- Complete epithelial repair takes about **4-5 weeks**, while complete repair of connective tissue takes about **7 weeks**

7- The gingival fluid increases after gingivectomy and diminished progresses, because decrease in vasodilation and vascularity. Also during the first 4 weeks after gingivectomy keratinisation is less than that prior to the surgery

Healing following a flap operation

Healing will be by first intention and has many similarities with healing of an incision in the skin. It is faster than secondary intention and characterised by formation of only minimal amounts of granulation tissue

Steps of healing

- 1- Immediately after suturing (0-24 h) a connection between flap and tooth or bone surface is established by the blood clot which consists of fibrin, PMNLs, erythrocytes, debris from injured cells and capillaries at the edge of the wounds, there are also bacteria and an exudates as a result of tissue injury
- 2- At 1-2 days after surgery, the space between the flap and tooth or bone is thinner, epithelial cells migrate over the border of the flap to contact the tooth. When the flap is closely adapted to the alveolar process, there is a minimal inflammatory response
- 3- One week after surgery: epithelial cells are attached to the root by hemidesmosomes and a basal lamina. The blood clot is replaced by granulation tissue derived from gingival connective tissue, the bone marrow and the PDL
- 4- Two weeks after surgery: appearance of collagen fibres parallel to the tooth surface. They are immature therefore the union is still weak, although clinically may be normal

One month after surgery: a fully epithelised gingival crevice with a well-defined epithelial attachment presents. There is a beginning of the functional arrangement of supra-crestal fibres

Periodontal wound healing after regenerative surgery

Soft tissue grafts placed on bone shrink by about 25%, while that placed on periosteum shrinks by about 50%

- Regeneration of the periodontium must include the formation of new cementum with inserting collagen fibres on previously periodontitis-involved root surfaces and the regrowth of the alveolar bone.
- However, whether regrowth of alveolar bone should always be considered a requirement for success following regenerative periodontal surgery is a matter of discussion (not always happens)
- The basis for this discussion is that a fibrous attachment may exist without opposing bone in a normal dentition, not affected by periodontitis in the presence of bone dehiscence and fenestrations after flap surgery the curetted root surface may be repopulated by four different types of cell:

1- Epithelial cell

2- Cells derived from gingival connective tissue

3- Cells derived from the bone

4- Cells derived from the periodontal ligament

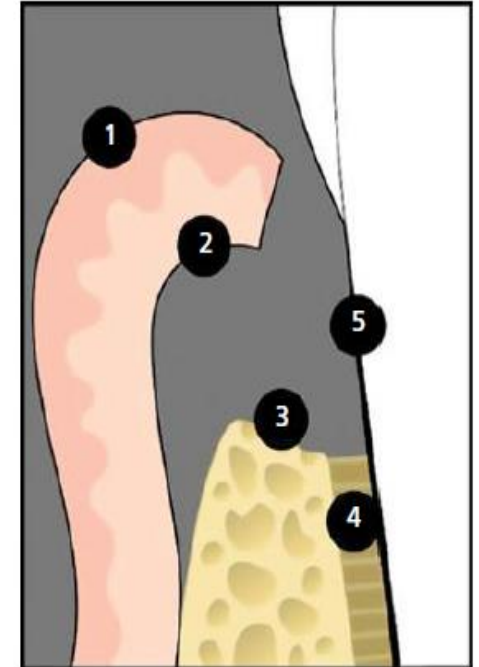


Fig. 27-3 Periodontal wound following flap surgery: (1) gingival epithelium; (2) gingival connective tissue; (3) alveolar bone; (4) periodontal ligament; and (5) cementum or dentin on the dental root surface.

Regenerative capacity of tissue cells

The ability of newly formed tissue originating from different type of periodontal cells to produce a new connective tissue attachment was examined in many studies and concluded that tissue derived from bone lacks cells with potential to produce a new connective tissue attachment

- Gingival connective tissue also lacks cells with potential to produce a new connective tissue attachment
- The cells of periodontal ligament seem the only ones, capable of **regenerating the lost periodontal attachment**

Factors affecting healing after periodontal treatment

I. Local factors

a. Local factors improve healing:

- Good debridement
- Immobilisation of the healing area
- Pressure on the wound
- An increase in O_2 consumption that increases cellular activity

b. Local factors delay healing

- Excessive tissue manipulation
- Trauma and presence of foreign bodies
- Repetitive treatment procedures that disrupt the orderly cellular activity in the healing process
- Inadequate blood supply lead to impaired cellular activity, leading to necrosis and delay healing

II. Systemic factors:

- Aging (diminishes capacity because of atherosclerotic vascular changes which reduce blood circulation)
- Patient with generalised infections
- Diabetes
- Patients with debilitating diseases
- Malnutrition: Vitamin C deficiency, protein deficiency
- Systemically administrated hormones as cortisone

Healing after implant placement

- A direct connection between bone and implant without interposed soft tissue layers termed as **osteointegration**
- Dr. Branemark (1952) defined osteointegration as a direct and functional connection between ordered, living bone and surface of a load carrying implant

Stages of osteointegration

After 24 hours

- Bone trabeculae in the apical portion of the implant dislocated into marrow space
- Blood vessels were served and bleeding occurred
- Blood clot formation can be observed between the implant body and the host bone

After one week

- There will be release of growth factors which activate fibroblast and formation of provisional connective tissue in the apical trabecular region and the inner part of the threaded region of implant

After two weeks

- Newly formed bone has been laid down on the implant

After 4 weeks

- Newly formed bone line most part of the implant surface which represents the first stage of true osteointegration

Final stage of osteointegration

- A stage of remodelling will occur during which that woven bone is substituted with lamellar bone

Factors influencing bone healing

1- Biological factors

- Health condition of the recipient bone
- Surgical and operative procedures
- Infection control

2- Chemical factors: properties of the implant material should be:
Biotolerant, Bioinert, Bioactive

3- Physical factors include:

- Size of implant-bone contact surface (interface)
- Implant shape retentive form to achieve primary retention and increase of implant surface
- Loading

References

- Clinical Periodontology and Implant Dentistry By Jan Lindhe
- Colour Atlas of Dental Medicine and Periodontology